MRI T2 RELAXATION TIME EVALUATION OF WRIST CARTILAGE WITH SCAPHOLUNATE LIGAMENT INJURY IN THE PRE-OPERATIVE AND POST-OPERATIVE STATE

By

Dannica Leigh Sturgeon

Submitted to the graduate degree program in Mechanical Engineering and the Graduate Faculty of the University of Kansas in partial fulfillment of the requirements for the degree of Master of Science in Mechanical Engineering.

_____

Co-Chairperson: Dr. Kenneth J. Fischer

_____

Co-Chairperson: Dr. Phil Lee

_____

Dr. Elizabeth A. Friis

Date Defended: 14 April 2011

The Thesis Committee for Dannica Leigh Sturgeon

certifies that this is the approved version of the following thesis:

MRI T2 RELAXATION TIME EVALUATION OF WRIST CARTILAGE WITH SCAPHOLUNATE LIGAMENT INJURY IN THE PRE-OPERATIVE AND POST-OPERATIVE STATE

_____

Co-Chairperson: Dr. Kenneth J. Fischer

_____

Co-Chairperson: Dr. Phil Lee

_____

Dr. Elizabeth A. Friis

Date approved: 27 April 2011

ABSTRACT

The overall goal of this research was to develop a method to non-invasively assess the cartilage of subjects exhibiting unilateral scapholunate dissociation. The research was completed with the hope of identifying the health status of the cartilage to aid in wrist injury assessment, treatment, and prevention of the osteoarthritis that often results from injury. A custom Matlab code was developed to calculate the transverse relaxation time, T_2, of cartilage in the wrist of the normal and injured wrists, in both pre-operation and post-operation scans. In the pre-operation study analysis, elevated T_2 values were observed in the injured wrist cartilage from the normal wrist values. The study analyzing correlations between pre-operation and post-operation scans resulted in elevated T_2 values observed in the post-operation injured wrists from the post-operation normal wrists. There was also a significant rise in injured wrist T_2 values between the pre-operation and post-operation scans. Continued data collection with enrollment of additional subjects will add to the significance of the results. The results indicate that calculating the T_2 value of cartilage may be an effective method of determining cartilage health status.

ACKNOWLEDGEMENTS

I would like to extend a big thank you to Dr. Kenneth J. Fischer for his acceptance of me as a graduate assistant in his lab, as well as the continued support and guidance he has provided throughout my graduate studies here at the University of Kansas. I would like to thank my graduate committee, Dr. Elizabeth A. Friis and Dr. Phil Lee, as well as the additional co-authors on the journal articles: Dr. Terence E. McIff and Dr. E. Bruce Toby. Thank you to the Department of Mechanical Engineering for the excellent education and graduate support I have received as a student here.

I would like to acknowledge NIH for the study support and the University of Kansas Medical Center's facilities and assistance at the Orthopedic Research Center and Hoglund Brain Imaging Center in Kansas City, KS. I would also like to thank the National Science Foundation for the fellowship I received through the NSF GK-12 Graduate STEM Fellows in Education program, which has been a wonderful experience and has provided financial support for me as I continued my research this past year.

Thank you to my family for their years and years of love and support. Your guidance has not only inspired me as to who I am and can become, but has also provided me with the priceless gift of a firm foundation in my faith. Thank you to my husband; without your encouragement and support, this would have not only been more difficult, but not nearly as much fun as this experience has been with you. I am so excited to see where the future takes us.

TABLE OF CONTENTS

TABLE OF FIGURES

1.0 BACKGROUND

1.1 SCAPHOLUNATE DISSOCIATION

1.1.1 Anatomy

The human body is composed of over 200 bones, responsible for its structure and support. Many bones are associated with the wrist and hand. Two of the bones, the radius and ulna, are in the distal forearm (1). The wrist and hand is then composed of the carpal bones, metacarpal bones, proximal phalanges, middle phalanges, and distal phalanges (2).The carpal bones can be divided into two rows, the proximal and distal rows. Of the eight carpal bones located in the wrist (proximal row: scaphoid, lunate, triquetrum, pisiform, and distal row: trapezium, trapezoid, capitate, and hamate), much of the overall wrist stability is achieved through the proper function of the scaphoid bone and the scapholunate joint (1).

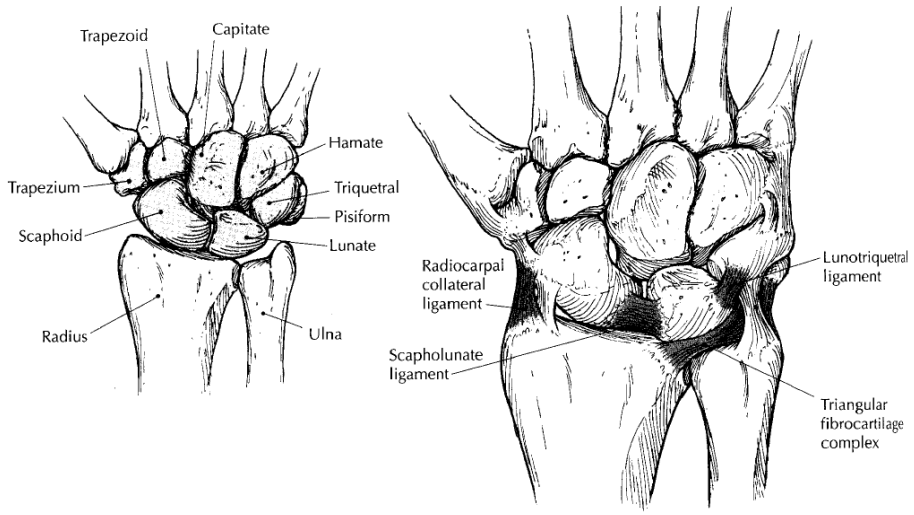

Figure 1.1 Bones of the wrist (left) and ligaments of the wrist (right). Reprinted with permission from Am Fam Physician. 1994; 49: 1845 – 1850.

The scapholunate interosseous ligament (SLL) is the most important of the inter-carpal ligaments (3). Its three segments , the volar (palmar), middle (proximal), and dorsal sections, have different functions. The dorsal segment, which is the shortest and thickest segment of the SLL, along with the palmar segment, is ligamentous in nature. The dorsal segment's collagen fibers run transversely, while the palmar segement is oriented obliquely and is thinner than the dorsal segment. The proximal segment, however, is comprised of fibrocartilage. While it directly connects to the dorsal segment, vascular tissue separates it from the palmar segment (4). Volar movement of the scaphoid and lunate is allowed by its corresponding segment, which is the longest of the three. The middle section of the ligament does not appear to provide stability to the wrist. Scapholunate stability is primarily provided by the dorsal segment of the SLL (3).

Stability of the wrist is the key to maintaining normal wrist function. If stability is compromised by the injury to the SLL, normal wrist function no longer occurs. The scaphoid rotates, the lunate and scaphoid dissociate, and abnormal stresses are imposed on the surrounding surfaces (1). Rupture of the primary stabilizing segment of the SLL, the dorsal segment, will lead to scapholunate dissociation (SLD) and rotatary subluxation of the scaphoid (RSS) (3). As the severity of the injury increases, the injury may advance to scapholunate advanced collapse, also known as SLAC wrist (5).

1.1.2 Scapholunate Injury

Injuries to the wrist commonly occur. More often than not, when a person hurts their wrist, the integrity of the SLL is compromised (1). A fall with the hand

outstretched (6) and motions involving rotation of the wrist (1) are common causes of this type of injury.

Symptoms of a damaged SLL are wide-ranging, varying from acute pain to only occasionally being uncomfortable. When an acute injury is sustained, the most immediate symptoms present are local swelling, ecchymosis (blood in tissues due to ruptured blood vessels (7)), and tenderness. If no medical help is sought, these immediate symptoms may decrease over time. Pain may only be present during certain activities or movements, wrist motion may be limited, and grip strength may be reduced as time progresses (1, 6). The wrist may also be stiff in the mornings, and experience clicking or popping during wrist rotation (1).

A physical exam can be given to patients with wrist injuries in an attempt to diagnose scapholunate dissociation. In addition to looking for the symptoms listed above, chronic patients may exhibit limitations in their range of wrist motion and amount of wrist flexion (1). The neurovascular status of the wrist should also be determined before deciding whether to continue with clinical assessments, such as Watson's scaphoid shift test (6). Watson's scaphoid shift test, in which an "audible and palpable click" is looked for by applying force to the distal part of the scaphoid, can be performed successfully in a clinical setting. During this test, the hand is in "passive radial deviation of the neutrally flexed wrist, starting in ulnar deviation" (1), to allow for the scaphoid to subluxate dorsally (1, 3). This test should be used with caution, however, as some people with hypermobile joints will produce this click normally in both wrists (1).

1.1.3 Scapholunate Dissociation

There are four stages of scapholunate dissociation, as defined by Watson and Ballet. During these stages, the SLL is undergoing many changes. Stage 1 is characterized by the SLL having a partial lesion (3), and by increasing contact pressures that lead to breaking the radial styloid. Stage two is reached with radioscaphoid arthrosis and joint narrowing (6). In this stage, the SLL ruptures, although other secondary stabilizing ligaments are still intact. When lesions of the secondary stabilizing ligaments appear as well, the injury has progressed to stage 3 (3). The secondary stabilizing ligaments include the radiolunate ligament, radioscaphocapitate ligament, and the radioscapholunate ligament (8). Arthrosis between the scaphoid/lunate and the capitate also indicates stage three. Stage four is classified as containing all signs of stages 1-3, as well as the radiolunate joint degenerating (6). The degenerative arthritis, beginning with the scaphoid and radius and progressing to the capitate and lunate, is the degeneration pattern coined by Watson and Ballet as SLAC wrist (9).

Although these stages (degeneration of the radial part of the radius-scaphoid joint, the whole of the mentioned joint, followed by degeneration of the capitate-lunate joint) described by Watson and Ballet (10) have widely been regarded as standard for classifying scapholunate dissociation, recent research shows that radioscaphoid degeneration does not necessarily occur before radiolunate degeneration. Lane et al. found that it is not always true that radiolunate articulation is unaffected by scapholunate dissociation, and that it may occur before radioscaphoid degeneration in some cases (11).

Other methods are used in addition to Watson's scaphoid shift test when evaluating a wrist injury. Commonly, radiographic evaluation is used to determine the status of the wrist injury. Correct wrist positions are very important when examining radiographs. Multiple views are often required to gain the full picture of what is happening with the bones. Standard posteroanterior and lateral radiographs (1, 6) are often accompanied with additional radiographs with the wrist deviated in the radial and ulnar directions, as well as with the hand in a forceful grip (1). Stecher's view, with the fist clenched while the wrist is in ulnar deviation, is also recommended, as well as views of the wrist in a 45° semipronated position (3, 6). Gilula's lines are observed, as well as looking for the presence of a "scaphoid ring sign" (1). The Gilula's lines normally appear smooth (6). Gilula's lines are three arcs that can be drawn across the carpal bones: one along the proximal convex cortical surfaces of the scaphoid, lunate and triquetrum; one along the distal cortical concavities of the scaphoid, lunate and triquetrum; and one along the proximal cortical convexities of the capitates and hamate (12). The ring sign, along with a spacing ≥ 3 mm between the scaphoid and the lunate, are indicators for scapholunate dissociation. A marker for scapholunate dissociation in the lateral view radiograph is when the scaphoid's long axis and the lunate form an angle >70° (1).

Wrist abnormalities can be hard to detect, and cannot always be found with standard radiographs even using all of the techniques listed above. Other methods of evaluating the wrist are available. Arthroscopy, although invasive, allows the inside of the wrist to be viewed directly (3). Instability can also be detected through the use of fluoroscopy, dynamic cineradiography, and wrist arthrography (1). Arthrography

utilizes dye to look for signs of ligament instability, and is often used in conjunction with other forms of assessment such as magnetic resonance imaging (MRI) or computed tomography (CT). Kinematography is suggested when there is no sign of instability through radiographs, but the patient is able to produce an audible sound through movement of their wrists (3). Direct imaging of the ligaments, however, can only be achieved through MRI (1, 3).

1.1.4 Treatment

Once a scapholunate injury has been identified, there are many options for treatment of the injury. Seeing as how not all injuries are the same, the treatments prescribed for scapholunate injuries are not always the same either. A recent acute injury often leads to a different treatment choice than a chronic case.

If scapholunate dissociation is determined within four weeks of injury, repair through operation is often recommended. Kirschner wires can be used to stabilize the scaphoid temporarily and allow healing to occur (1). Surgery, which is widely recommended, often involves ligament repair and dorsal intercarpal ligament capsulodesis (3).

Surgery is also performed in some longer term cases with no signs of joint degeneration, although the long-term success of these surgeries is still questionable (1, 3). However, if the patient has extreme pain and the joints in their wrist are unstable, surgery to repair the wrist may be required, in which mobility is compromised but pain is reduced. Severe chronic cases may require reconstruction surgery that aims to reduce pain, but hinders wrist movement and does not necessarily

stop degeneration from occurring (1). Common surgical methods are the modified Brunelli technique (13-15), fusion, and direct repair. These three methods have been utilized for the patients in this study.

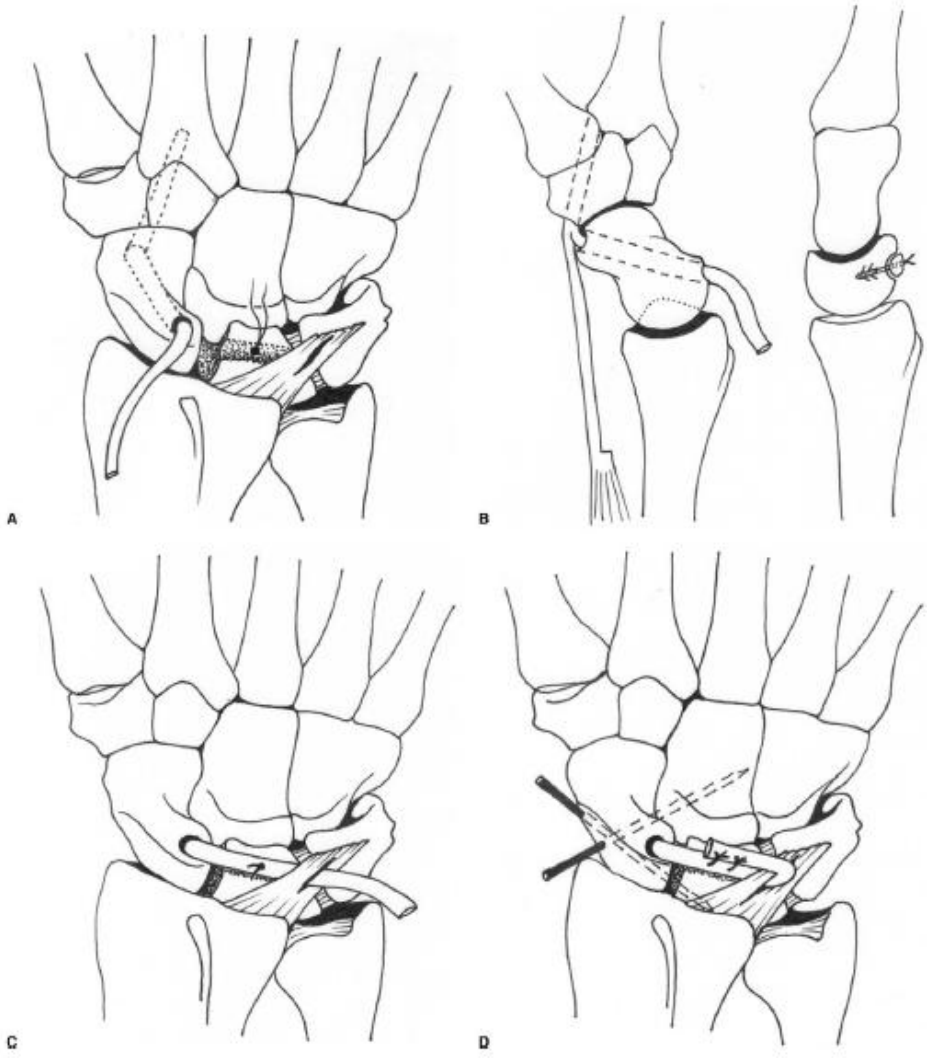

Figure 1.2 Example of the modified Brunelli technique as presented by Garcia-Elias. A – a strip of the flexor carpi radialis tendon is run through the scaphoid. B – The tendon is run across the scapholunate joint and sutured to the lunate. C – The tendon is passed through a slit made in the dorsal radiotriquetral ligament. D – The graft is sutured onto itself with two K-wires holding the scapholunate and scaphocapitate joints. Reprinted from the Journal of Hand Surgery, 31, Garcia-Elias M, Lluch AL, Stanley JK, Three-Ligament Tenodesis for the Treatment of Scapholunate Dissociation: Indications and Surgical Technique, 125-134, 2006, with permission from Elsevier.

More conservative forms of treatment are often selected in patients presenting chronic scapholunate dissociation. Conservative treatment includes stabilization and anti-inflammatory medication. Patients are also instructed to stretch and strengthen the wrist through exercises. Although this form of treatment can be effective, it is often difficult to successfully implement in active individuals striving to resume normal activities (1).

1.1.5 Altered Kinematics

While surgery aims to restore joint motion, reduce pain, and improve the patient's overall quality of life, degeneration of the joint does not necessarily cease following surgery. Developing osteoarthritis (OA) in the wrist following scapholunate injury/surgery is common (1, 3, 5-6, 9-10, 16-22). Monitoring the status of the cartilage is an important component of the health care the patient receives.

When the SLL suffers damage, the motion pattern and alignment of the bones are altered. Pain experienced by the patient may be due to this, and over time, osteoarthritis commonly develops (5). It is accepted that untreated SLL injury, progressing to SLAC wrist, will show signs of degeneration in the wrist joints. Watson et al., even classified the degeneration due to the injury as having three different stages. The first stage was proposed as being degeneration between the scaphoid and radial styloid. The second stage was degeneration advancing along the rest of the radioscaphoid joint. Degeneration at the capitolunate joint was classified as the third stage of the SLAC wrist (10). Weiss et al. reports that "…chronic scapholunate tears in particular are known to produce intercarpal instability, altered wrist kinematics and joint loading, and degeneration of the radiocarpal joint." (22).

1.2 OSTEOARTHRITIS

1.2.1 Definition

Injury to the scapholunate interosseous ligament, and the resulting abnormal bone alignment, often ultimately leads to osteoarthritis in the wrist. Osteoarthritis is the most common joint disorder, causing pain with movement of the affected joint (23). Almost fourteen percent (13.9%) of the population of the United States aged 25 years and older is affected by osteoarthritis. Over one-third of people aged 65 years and older are affected by osteoarthritis (33.6%) (24). Osteoarthritis is illustrated by a loss of hyaline articular cartilage (25) and breakdown of the extracellular matrix (26) in which chondrocytes lose the ability to maintain the proper functionality of the cartilage (27). As cartilage is lost with degeneration, the cartilage will try to repair itself and will also experience subchondral bone remodeling and sclerosis, as well as the appearance of cysts and osteophytes (27).

Changes are present in the cartilage during all states of osteoarthritis. In the early stages of OA, areas of the cartilage swell, causing an uneven cartilage surface. The collagen network becomes disorganized in addition to proteoglycan breakdown and increased water within the cartilage. As osteoarthritis progresses, the damage to the articular surface of the cartilage progresses; the surface can no longer trap the proteoglycans. The proteoglycans begin to diffuse into the synovial fluid, causing a decrease in the water content of the cartilage. Fibrillation, caused by the lesions in the cartilage reaching deeper layers of the cartilage, indicates intermediate osteoarthritis. The cartilage also experiences detachment in areas, and begins to thin in areas with high wear. Proteoglycan and water content in the cartilage decreases

further as the fibrillation (either in local areas or throughout the surface) advances. Late osteoarthritis shows even further reduction of proteoglycans, water, and collagen content within the cartilage. Fibrillation of the cartilage becomes severe as the degeneration continues; thinning enough to expose the bone in areas. The collagen network in the cartilage is very disorganized as the tissue continues to erode (26).

SLAC is the most common cause of osteoarthritis in the wrist, with 55% of wrist osteoarthritis cases (18). Symptoms can vary from person to person, with osteoarthritis severity impacting the magnitude of the symptoms experienced. As joint degeneration is experienced, symptoms experienced can include swelling, pain, and limited motion of the affected joints (22).

1.2.2 Causes

Osteoarthritis stems from a variety of causes. Wrist arthritis, in general, can stem from idiopathic and traumatic causes. Congenital conditions (e.g.: Madelung's deformity) can cause pancarpal osteoarthritis. Idiopathic causes of radiocarpal osteoarthritis also includes Kienbock's and Presiser's disease. The scaphotrapezium-trapezoid commonly experiences osteoarthritis while showing no signs of joint degeneration in the other wrist joints (22).

Injuries to ligaments in the wrist can also lead to osteoarthritis. Scaphoid fracture and nonunion, leads to the condition scaphoid nonunion advanced collapse (SNAC) wrist, and leads to arthritis throughout the wrist (22). A wrist sprain, leading to SLAC wrist, is the most common cause of radiocarpal osteoarthritis (18) and ultimately leads to pancarpal arthritis (22).

1.2.3 Detection

Detection of osteoarthritis involves clinical and other advanced means of detection. Clinically, it is very important to palpate the wrist joints to determine the locations that exhibit the most tenderness and/or crepitus (22).

Radiological examination is commonly performed to identify osteoarthritis. Posteroanterior, lateral (18, 22), and oblique (18) radiographs are taken of the wrist to determine which joints are the ones affected by OA. Radiological indicators of OA include: narrowing of the radioscaphoid and radiolunate joints, osteophytes, subchondral sclerosis, and cysts. Although each joint in the wrist should be examined for signs of OA, special attention should be given to the head of the capitate (22).

Criteria have been established to detect osteoarthritis using radiology; looking for degenerative, reparative, and inflammatory features in the joint. Radiographic assessment of cartilage allows for the grading of the severity of osteoarthritis present. The grades, developed by Kellgren and Lawrence, divide osteoarthritis into four categories (23):

Grade 1: Doubtful narrowing of joint space and possible osteophytic lipping,

Grade 2: Definite osteophytes and possible narrowing of joint space,

Grade 3: Moderate multiple osteophytes, definite narrowing of joint space, and some sclerosis and possible deformity of bone ends,

Grade 4: Large osteophytes, marked narrowing of joint space, severe sclerosis, and definite deformity of bone ends.

Other detection methods for OA, such as MRI and bone scintigraphy, are not as commonly employed in OA detection but are useful in detecting subtle OA cases that are not as apparent on radiographs (22). Direct assessment of the cartilage in the

wrist can be accomplished through modes such as CT-arthrography, MRI, and MR-arthrography. These modalities can provide further insight into joint degeneration than radiography, with MR-arthrography providing the best assessment of the cartilage (18).

1.2.4 Treatment

Treatment of osteoarthritis, as with treatment of SLL injuries, widely varies. Osteoarthritis, stemming from any of the aforementioned causes, can be treated by conservative and/or surgical means.

Conservative treatment is often more effective in wrists with early stages of osteoarthritis. Options for treatment include splinting or putting a cast on the wrist, nonsteroidal anti-inflammatory medicines, and certain intra-articular corticosteroid injections (22). Conservative treatment options are typically selected as a temporary solution while deciding what type of treatment to pursue (21). The goal of these treatment options is not to cease advancement of the osteoarthritis degeneration, but to provide pain relief and wrist function for the patient. As degeneration continues, pain often becomes too great for conservative means, and surgery becomes a more viable treatment option. The main goals of surgery in an osteoarthritic wrist are to preserve motion in the affected joints where possible, while removing the pain due to the osteoarthritis (22).

1.3 NON-INVASIVE CARTILAGE EVALUATION

1.3.1 Methods

While osteoarthritis is commonly detected radiologically without the injection of any contrast mediums, this method fails to allow direct visualization of the cartilage;

knowledge about the state of the cartilage must be extracted from the appearance of the bones on the radiograph. By directly imaging the cartilage, joint degeneration may be apparent at much earlier stages than through radiography.

Direct analysis of the cartilage state in a patient can be accomplished through many modes, including: arthrography (28), computed tomographic arthrography, magnetic resonance imaging, magnetic resonance arthrography (18), and bone scintigraphy (22). Arthroscopy is the accepted gold standard when observing cartilage. Arthroscopy, although effective in cartilage assessment, does not come without problems. This technique is invasive, expensive, and provides visual information only about the surface of the cartilage. The hardness of the cartilage can be qualitatively tested with a small metal probe. Biopsies can also be obtained when arthroscopy is being performed, although this is often a point of hesitation for patients (29).

1.3.2 Magnetic Resonance Imaging

The non-invasive, high quality nature of magnetic resonance imaging (MRI) makes it an effective means of assessing cartilage, ligaments, and other soft tissues. MRI has been utilized frequently for imaging cartilage in osteoarthritis cases, and has emerged as a useful modality of cartilage evaluation. Blumenkrantz et al. states that "Magnetic resonance (MR) imaging is ideal for monitoring arthritis. MR offers mulit-planar capabilities, high spatial resolution without ionizing radiation, and superior contrast between joint tissues…" (25). Gold et al. states that "MR imaging, with its excellent soft tissue contrast, is the best technique available for assessment of cartilage injury and repair." Ideally, MRI would give accurate information about the

thickness of the cartilage, cartilage surface characteristics, internal cartilage changes, and information about the subchondral bone (29). Although these are not all perfected in the imaging schemes available, each technique offers different advantages.

Common MR imaging techniques include: sodium MRI (30), quantitative MRI for cartilage volume/thickness, $T_{1\rho}$, dGEMRIC, and T_2 mapping (25). Sodium MRI measures the proteoglycan content of the cartilage being assessed. A three-dimensional fast gradient-echo sequence is employed to attain the images. The amount of sodium present in the cartilage directly relates to the fixed negative charge density of the cartilage, which in turn relates to the proteoglycan concentration. The sodium T_1 and T_2 values increase as the proteoglycan content decreases (30).

When calculating the cartilage volume and thickness, images with high-resolution can be used to be able to clearly define the boundaries of the cartilage. Sequences such as fat-supressed spoiled gradient echo and fast double echo and steady state (DESS) with water-excitation provide high quality images for segmenting cartilage. Cartilage thickness and volume estimates can be extracted from the information attained through segmenting the cartilage in the MR images (25).

$T_{1\rho}$ mapping is sensitive to the proteoglycan (PG) content of the cartilage, which is what provides cartilage with its crucial qualities of elasticity and resilience. The sequence consists of:

> …a $\pi/2$ pulse applied along the x-axis flips the longitudinal magnetization into the transverse plane along the y-axis. Then, a long, low power pulse is applied long the y-axis to spin-lock the magnetization. The second $\pi/2$ pulse flips this spin-locked magnetization back to the z-axis. Residual transverse magnetization is

then dephased by a crusher gradient. Magnetization stored along the z-axis is then read out by a fast spin echo (FSE) sequence or a gradient echo sequence (25).

After completing the sequence, different spin-locking times (TSL) will have been acquired, as well as the corresponding signal (S) as each one. Using the following equation, the $T_{1\rho}$ can be calculated: $S(TSL) \propto e^{(-TSL/\ T1\rho)}$ (25).

dGEMRIC imaging indirectly measures the glycosaminoglycan (GAG) concentration by measuring how much uptake is experienced by a contrast agent, such as Gd-DTPA. The agent, delivered intra-venously, has a negative charge and is absorbed by the cartilage. GAG is also negative in charge, so in healthy cartilage with high levels of GAG, not much of the contrast agent is absorbed. The opposite can be said for unhealthy cartilage, in which the levels of GAG in the cartilage are lowered. The T_1 relaxation time is calculated to be able to gain understanding as to the distribution of the contrast agent in the cartilage (25).

T_2 relaxation time is a very useful tool to measure the integrity of cartilage. It is a non-invasive method of attaining information regarding cartilage hydration and biochemical composition, changes in which are markers for cartilage degeneration. When water is immobilized in the cartilage by a healthy collagen-proteoglycan matrix, it results in low signal intensity on long echo time (long-TE) images, and therefore low T_2 relaxation times. As water escapes entrapment of the articular cartilage and makes its way into the synovial fluid with degeneration of the cartilage, the signal intensity does not lower on long-TE images, resulting in higher T_2 times. Thus, as cartilage degenerates and the collagen and proteoglycan depletion

progresses, the T_2 relaxation time of the cartilage increases as water becomes more mobile (25).

To obtain T_2 relaxation time information: "Typically, T_2 –weighted multi-echo, spin echo images with varying echo times (TE) and identical repetition times (TR) are acquired… T_2 is defined as the time at which the signal decays to 37% of the maximum signal." T_2 relaxation time is calculated according to the following equation: $S(TE) \propto e^{(-TE/T2)}$ (25).

In vitro studies have been completed analyzing T_2 relaxation times and their relationships to mechanical and biochemical properties of cartilage. One study showed that mechanical properties such as Young's Modulus correlate to T_2 times in cartilage (31). Although proteoglycan levels and T_2 relaxation times have not been shown to correlate, it is accepted that hydration and collagen matrix integrity are directly related to the calculated T_2 relaxation time; as degeneration continues the T_2 time increases (25).

T_2 relaxation times in cartilage may also be affected by the age of the patient, according to an in vivo study (32). An in vivo knee study showed that T_2 relaxation times were significantly different between healthy and osteoarthritic cartilage in all but one of the knee compartments analyzed, although no differences were seen in the T_2 relaxation times in cartilage between different stages of osteoarthritis. Mean values of T_2 relaxation times in cartilage with knee osteoarthritis in healthy subjects were calculated to be 32.1-35.0 msec, while osteoarthritic cartilage was calculated to have values ranging from 34.4-41.0 msec (33). In a paper presented by Gold et al. a

figure presents T_2 relaxation time being assumed as 40 ms for articular cartilage, and 250 ms for synovial fluid (29). In a study with multiexponential analysis of T_2 relaxation times in bovine cartilage, three different times were detected: 2.3 ms, 25.2 ms, and 96.3 ms (34). In a study of healthy subjects, the mean T_2 times seen in the proximal interphalangeal joint of the index finger ranged from 42-66 msec in different areas of the cartilage (35). The range of T_2 relaxation times seen in literature suggests that more study and research into T_2 relaxation time in required to fully understand the extent and range of correlations to be made between T_2 relaxation times and articular cartilage, and the best method in which to achieve it.

1.4 REFERENCES

1. Atkinson LS, Baxley EG. Scapholunate dissociation. Am Fam Physician. 1994; 49:1845-1850.
2. Netter FH. Atlas of Human Anatomy. Fourth Edition ed. Philadelphia, PA: Saunders/Elsevier, 2006.
3. Schmitt R, Froehner S, Coblenz G, Christopoulos G. Carpal instability. Eur Radiol. 2006; 16:2161-2178.
4. Berger RA, Imeada T, Berglund L, An KN. Constraint and material properties of the subregions of the scapholunate interosseous ligament. J Hand Surg Am. 1999; 24:953-962.
5. Tanaka T, Ogino S, Yoshioka H. Ligamentous injuries of the wrist. Semin Musculoskelet Radiol. 2008; 12:359-377.
6. Peterson B, Szabo RM. Carpal osteoarthrosis. Hand Clin. 2006; 22:517-528; abstract vii.
7. ecchymosis. Webster's New Collegiate Dictionary. Springfield, MA: G. & C. Merriam Company, 1981.
8. Ruby LK. Wrist biomechanics. Instr Course Lect. 1992; 41:25-32.
9. Watson HK, Ballet FL. The SLAC wrist: scapholunate advanced collapse pattern of degenerative arthritis. J Hand Surg Am. 1984; 9:358-365.
10. Watson HK, Ryu J. Evolution of arthritis of the wrist. Clin Orthop Relat Res. 1986:57-67.
11. Lane LB, Daher RJ, Leo AJ. Scapholunate dissociation with radiolunate arthritis without radioscaphoid arthritis. J Hand Surg Am. 2010; 35:1075-1081.

12. Wrist: terminology and definitions. J Bone Joint Surg Am. 2002; 84-A Suppl 1:1-73.

13. Garcia-Elias M, Lluch AL, Stanley JK. Three-ligament tenodesis for the treatment of scapholunate dissociation: indications and surgical technique. J Hand Surg Am. 2006; 31:125-134.

14. Talwalkar SC, Edwards AT, Hayton MJ, Stilwell JH, Trail IA, Stanley JK. Results of tri-ligament tenodesis: a modified Brunelli procedure in the management of scapholunate instability. J Hand Surg Br. 2006; 31:110-117.

15. Van Den Abbeele KL, Loh YC, Stanley JK, Trail IA. Early results of a modified Brunelli procedure for scapholunate instability. J Hand Surg Br. 1998; 23:258-261.

16. Ferreres A, Garcia-Elias M, Plaza R. Long-term results of lunocapitate arthrodesis with scaphoid excision for SLAC and SNAC wrists. J Hand Surg Eur Vol. 2009; 34:603-608.

17. Feydy A, Pluot E, Guerini H, Drape JL. Role of imaging in spine, hand, and wrist osteoarthritis. Rheum Dis Clin North Am. 2009; 35:605-649.

18. Feydy A, Pluot E, Guerini H, Drape JL. Osteoarthritis of the wrist and hand, and spine. Radiol Clin North Am. 2009; 47:723-759.

19. Hergenroeder PT, Penix AR. Bilateral scapholunate dissociation with degenerative arthritis. J Hand Surg Am. 1981; 6:620-622.

20. Kiefhaber TR. Management of scapholunate advanced collapse pattern of degenerative arthritis of the wrist. J Hand Surg Am. 2009; 34:1527-1530.

21. Talwalkar SC, Hayton MJ, Stanley JK. Wrist osteoarthritis. Scand J Surg. 2008; 97:305-309.

22. Weiss KE, Rodner CM. Osteoarthritis of the wrist. J Hand Surg Am. 2007; 32:725-746.

23. Jacobson LT. Definitions of osteoarthritis in the knee and hand. Ann Rheum Dis. 1996; 55:656-658.

24. Osteoarthritis. Atlanta, GA: Centers for Disease Control and Prevention.

25. Blumenkrantz G, Majumdar S. Quantitative magnetic resonance imaging of articular cartilage in osteoarthritis. Eur Cell Mater. 2007; 13:76-86.

26. Dijkgraaf LC, de Bont LG, Boering G, Liem RS. The structure, biochemistry, and metabolism of osteoarthritic cartilage: a review of the literature. J Oral Maxillofac Surg. 1995; 53:1182-1192.

27. Buckwalter JA, Martin JA. Osteoarthritis. Adv Drug Deliv Rev. 2006; 58:150-167.

28. Arthrography. University of Rochester Medical Center, 2008.

29. Gold GE, Beaulieu CF. Future of MR imaging of articular cartilage. Semin Musculoskelet Radiol. 2001; 5:313-327.

30. Borthakur A, Shapiro EM, Akella SV, Gougoutas A, Kneeland JB, Reddy R. Quantifying sodium in the human wrist in vivo by using MR imaging. Radiology. 2002; 224:598-602.

31. Lammentausta E, Kiviranta P, Nissi MJ, Laasanen MS, Kiviranta I, Nieminen MT, Jurvelin JS. T2 relaxation time and delayed gadolinium-enhanced MRI of

cartilage (dGEMRIC) of human patellar cartilage at 1.5 T and 9.4 T: Relationships with tissue mechanical properties. J Orthop Res. 2006; 24:366-374.

32. Mosher TJ, Dardzinski BJ, Smith MB. Human articular cartilage: influence of aging and early symptomatic degeneration on the spatial variation of T2--preliminary findings at 3 T. Radiology. 2000; 214:259-266.

33. Dunn TC, Lu Y, Jin H, Ries MD, Majumdar S. T2 relaxation time of cartilage at MR imaging: comparison with severity of knee osteoarthritis. Radiology. 2004; 232:592-598.

34. Reiter DA, Lin PC, Fishbein KW, Spencer RG. Multicomponent T2 relaxation analysis in cartilage. Magn Reson Med. 2009; 61:803-809.

35. Lazovic-Stojkovic J, Mosher TJ, Smith HE, Yang QX, Dardzinski BJ, Smith MB. Interphalangeal joint cartilage: high-spatial-resolution in vivo MR T2 mapping--a feasibility study. Radiology. 2004; 233:292-296.

2.0 Scapholunate Ligament Injury Alters MRI Relaxation Time in Wrist Cartilage

Dannica L. Sturgeon[1]; Phil Lee[2,3]; Terence E. McIff[4]; E. Bruce Toby[4], Kenneth J. Fischer[1,4]

[1]Department of Mechanical Engineering, University of Kansas, Lawrence, KS, 66045, USA

[2]Hoglund Brain Imaging Center, University of Kansas Medical Center, Kansas City, KS, 66160, USA

[3]Department of Molecular & Integrative Physiology, University of Kansas Medical Center, Kansas City, KS, 66160, USA

[4]Department of Orthopedic Surgery, University of Kansas Medical Center, Kansas City, KS, 66160, USA

Kenneth J. Fischer, PhD

Learned Hall
1530 W. 15th St, Room 3138
Lawrence, KS 66045-7609, USA

785-864-2994 (telephone)

785-864-5254 (fax)

fischer@ku.edu

Running title of 5 words or less: Wrist Cartilage T_2 Relaxation Time

2.1 ABSTRACT

The overall goal of this research is to identify completely non-invasive in vivo markers of cartilage damage following wrist injury in order to facilitate assessment and treatment of wrist injuries and prevention of osteoarthritis as a result of injury. In this study, the transverse relaxation time, T_2, of the wrist cartilage of subjects exhibiting unilateral scapholunate dissociation was analyzed to evaluate changes in the biochemical status of the cartilage in the wrist following injury. Data collection consisted of MRI scans of the wrist using a Siemens Allegra 3T scanner and a custom-built wrist coil. The T_2 trends from all subjects indicated that a higher value is associated with an injured wrist when analyzing means by bone. Pooled T_2 values in the injured wrist were significantly higher than those in the normal (contralateral) wrist ($p < 0.05$). Our data confirms that cartilage T_2 relaxation time consistently increases with injury to the wrist.

Keywords: MRI, T_2 relaxation time, scapholunate dissociation, articular cartilage, osteoarthritis

2.2 INTRODUCTION

Hand and wrist injuries commonly occur, and some can be debilitating. Scapholunate dissociation results from an injury to the scapholunate ligament (SLL) and generally requires surgery to restore normal biomechanics. If left untreated, scapholunate dissociation can lead to scapholunate advanced collapse (SLAC wrist) and associated osteoarthritis (1). The integrity of the scapholunate interosseous ligament is often compromised when a person hurts their wrist (2). A fall on the outstretched hand (3) and motions involving rotation of the wrist are common causes of this type of injury. Normal wrist function cannot occur if stability is disrupted by injury to the SLL. The scaphoid rotates, the lunate and scaphoid dissociate, and abnormal stresses are imposed on the surrounding articular surfaces (2). Rupture of the primary stabilizing segment of the SLL, the dorsal segment, will lead to scapholunate dissociation and rotatary subluxation of the scaphoid (4). As the severity of the injury increases, the injury is more likely to advance to SLAC wrist (5). The overall goal of this research is to identify completely non-invasive in vivo markers of cartilage damage following wrist injury in order to facilitate assessment and treatment of wrist injuries and prevention of osteoarthritis as a result of injury.

When diagnosing scapholunate dissociation, radiography is commonly employed. Standard posteroanterior and lateral radiographs (2-3) are often accompanied with additional radiographs with the wrist deviated in the radial and ulnar directions, as well as with the hand in a forceful grip (2). Direct non-invasive imaging of the ligaments, however, can only be achieved through MRI (2, 4).

The non-invasive, high quality nature of magnetic resonance imaging (MRI) makes it an effective means of assessing cartilage, ligaments, and other soft tissues. MRI has been utilized frequently for imaging cartilage in osteoarthritis cases, and is emerging as a very useful modality of cartilage evaluation. Blumenkrantz et al. (6) comments on the benefits of MRI for monitoring arthritis, stating that its multi-planar and high spatial resolution images provide excellent joint tissue visualization without the use of any ionizing radiation. The excellent contrast provided by MRI for soft tissues such as cartilage is cited by Gold et al. as making MRI the best assessment technique for injuries and repairs to cartilage (7).

Many types of MRI techniques have been utilized, including sodium MRI(8), quantitative MRI for cartilage volume and thickness, longitudinal relaxation time in the rotating frame ($T_{1\rho}$), delayed gadolinium-enhanced MRI of cartilage (dGEMRIC), and transverse relaxation time (T_2) (6). Sodium MRI is sensitive to proteoglycan content in the cartilage because of the attraction of sodium to the fixed negative charge density of GAGs in the cartilage, the magnitude of which correlates to the PG content (8). To obtain cartilage volume and thickness information, images with high-resolution are needed to clearly identify the cartilage boundaries; fat-supressed spoiled gradient echo and fast double echo and steady state (DESS) with water-excitation sequences are used to obtain these images. $T_{1\rho}$ mapping is sensitive to proteoglycan (PG) content, and may be used to directly assess changes in PG. The dGEMRIC imaging sequence refers to the indirect measure of glycosaminoglycan (GAG) concentration in cartilage by observing the amount of contrast agent uptake over a period of time in the cartilage and calculating the T_1 relaxation time (6).

T_2-weighted MRI has been extensively used in clinical setting to characterize alterations of tissue in injury or diseases because T_2 is sensitive to the alterations of biophysical and biochemical environment of water molecules in tissue. Compared to other MRI techniques, T_2 measurement in cartilage can be readily achievable in clinical setting without requiring additional hardware (e.g., sodium MRI), contrast agent administration (e.g., dGEMRIC), or relatively long acquisition time (e.g. $T_{1\rho}$). Parametric T_2 mapping provides added advantage in that the tissue contrast is not dependent on confounding factors in T_2-weighted images including proton density, longitudinal relaxation time, repetition time and radio-frequency probe inhomogeneity. It provides information regarding changes of hydration state and biochemical composition of cartilage, changes in which are markers for cartilage degeneration. When water molecules are immobilized in the cartilage by a healthy collagen-proteoglycan matrix, T_2 of water in the cartilage becomes shorter due to the reduced effect of motion averaging, which results in low signal intensity on long echo time (long-TE) MRI. As water escapes entrapment of the articular cartilage and makes its way into the synovial fluid with degeneration of the cartilage, T_2 of the water becomes longer due to the increased mobility of water molecules. Thus, as cartilage degenerates and the collagen and proteoglycan depletion progresses, the T_2 relaxation time of the cartilage increases as water becomes more mobile (6).

The objective of this study was to evaluate changes in the biophysical and biochemical status of the cartilage in the wrist following scapholunate ligament injury by measuring the T_2 relaxation times in the cartilage of human subjects. Thus, our

hypothesis was that the calculated T_2 relaxation time would be higher in the cartilage of injured wrists than in that of contralateral (assumed normal) controls.

2.3 METHODS

The study protocol was approved by the University of Kansas Medical Center's Human Subjects Committee. Data was collected from MRI of the radiocarpal joints in seven human subjects who exhibited unilateral scapholunate dissociation. Prior to scanning, the subject's pain levels associated with completing a grip strength task were recorded. Pain levels were measured on a 0-10 visual-analog scale (zero indicated no pain; increasing numbers with increased pain. 10 indicated unbearable pain).

Data collection consisted of MRI scans of the wrist using a Siemens Allegra 3T scanner (Siemens Medical Solutions USA, Inc., Malvern, PA) and a custom wrist coil. The scan series included a set of 4 spin echo scans (0.39 x 0.39 x 0.6 mm/pixel) with varying echo times (20, 40, 60, and 80 ms) to allow the calculation of cartilage T_2. This resulted in a set of 19 images for each echo time. These scans were taken with the patient's wrist in a relaxed state. The imaging protocol and analysis were performed on both the injured and contralateral wrist, which had not experienced any previous injuries.

The four image sets obtained from the spin echo scans were first co-registered to minimize the effects of any position changes over the set of 4 scans. Co-registration was performed with Analyze 5.0 (AnalyzeDirect, Inc., Overland Park, KS). Twenty-five automatic iterations of co-registration were completed after carrying out a manual registration. The magnitudes of image movement were analyzed before manually selecting the best co-registration to be utilized in image analysis. The regions of

radiocarpal cartilage on the radius and lunate bones in the wrist were then defined manually on the 60 ms image set using Adobe Photoshop Elements 8.0 (San Jose, CA). Only the central portion of the cartilage was included in the template, to avoid partial volume effects at the cartilage edges (Figure 2.1). The template was created by defining the cartilage pixels to have an intensity of zero and saving the image as an 8-bit gray scale image.

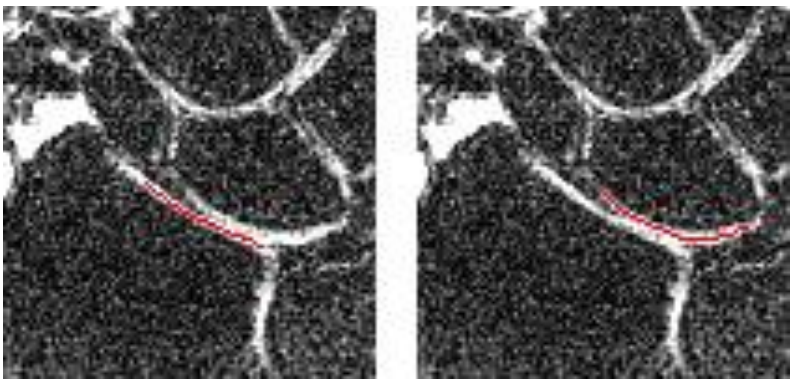

Figure 2.1 Example of radius (left) and lunate (right) cartilage template (image taken from 60 ms echo time image set at 0.39x0.39.0.6 mm/pixel).

After this, the data was analyzed by a custom Matlab code to calculate the T_2 value for each pixel of cartilage via linear regression to a semi-log plot of echo time vs. the natural logarithm of signal intensity (Figure 2.2). The T_2 values were calculated according to the following equation: $S(TE) \propto e^{(-TE/T2)}$ where S is the signal acquired at different echo-times (TE)(6). Pixels were deemed acceptable for statistical analysis after being filtered with a three-step process: 1) Individual pixel regressions that produced negative T_2 times were discarded; 2) Only pixel regressions with a correlation coefficient (R^2 value) of 0.6 or greater were considered to have reasonable "goodness of fit" for

inclusion of the T_2 data (all other pixels were discarded); 3) Pixels with outlier T_2 times (outside the range of mean ± 3 standard deviations), were omitted in an iterative fashion until all remaining pixels were within the acceptable range. This procedure reduced the possible effect of spatial mismatch among T2 data sets from incomplete co-registration and/or through-plane movement of the wrist, with an average of 27% of the original pixels defined as cartilage passing through the data filter.

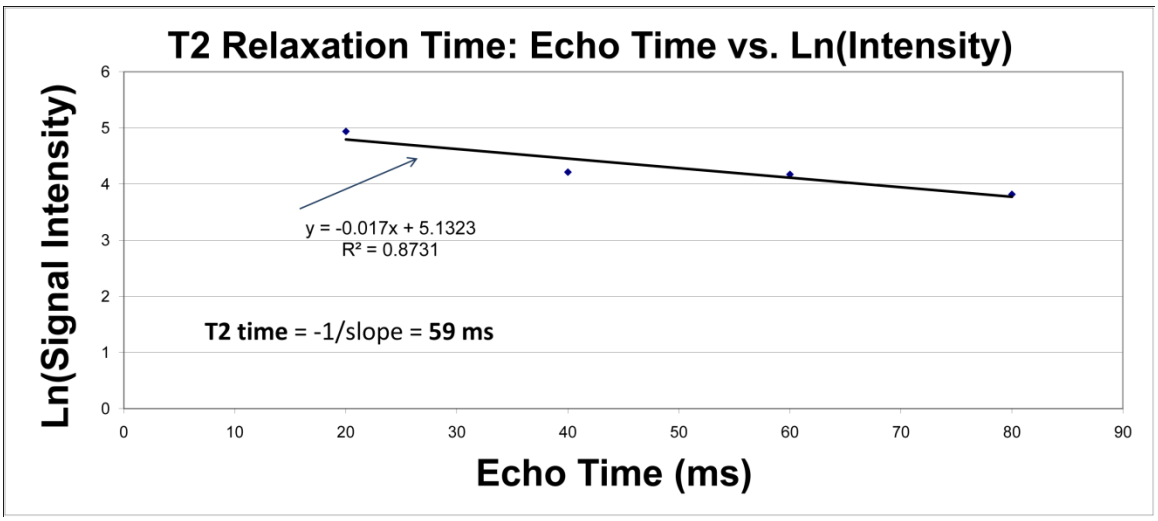

Figure 2.2 Example T_2 relaxation time calculation for a pixel of cartilage. Echo time in milliseconds is plotted with the natural logarithm of the signal intensity attained from one pixel location in each of the four echo time image sets. The T_2 time is the negative reciprocal of the slope, as determined by a linear fit of the four points.

Once the evaluation pixels were defined, the average intensity of the pixels was computed for each of the four echo times. A single, averaged T_2 was calculated from these four values and recorded. Descriptive statistics were calculated for the image set and the mean T_2 values for each bone were compared between the control and injured wrists, using paired t-tests ($p<0.05$ significant). In addition, regression analysis was performed to detect any relationships between the measures in the study.

2.4 RESULTS

Results indicated a consistent trend for higher mean T_2 time for the injured wrist. Regression analysis detected a significant relationship only between injured radius T_2 and injured lunate T_2 values. For all subjects analyzed, the mean T_2 value was higher for the injured wrist than for the normal wrist in both the radius and the lunate cartilage (Table 2.1). The T_2 time trends from all subjects also indicated that a higher T_2 time is associated with an injured wrist when analyzing means by bone (Figure 2.3). A significant difference was found between all pooled pre-op normal and injured T2 values, with higher T2 values occurring in the injured wrist. This finding supports the study hypothesis.

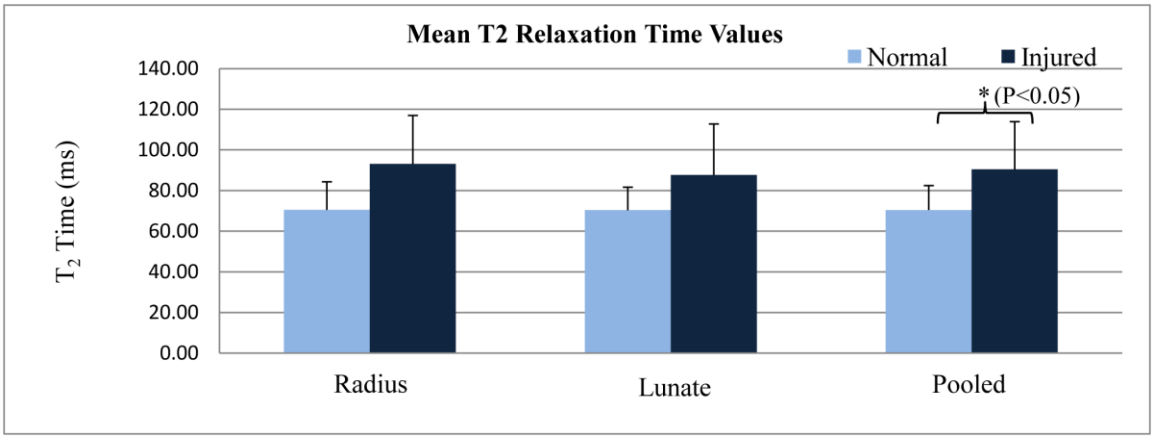

Figure 2.3 Mean T_2 values (error bars + 1 standard deviation) for control and injured wrist radius cartilage, lunate cartilage, and pooled data.

Pain reported from completing the grip test, as well as the time elapsed between the date of injury until the scan date are shown with the injured T_2 values in Table 2.1. Although the highest T_2 relaxation times calculated appear in the most recent injury,

regression analysis showed that T_2 value does not consistently correspond to time from injury.

The subjects with the very recent injuries, 20100311_01 and 20100702_01, both showed values in pain levels in the upper half of the 0-10 pain scale. This suggests that recent injuries are commonly associated with elevated pain levels, although this was not supported by the regression analysis. All remaining subjects showed values in pain in the lower half of the scale with the exception of one long-term patient, 20100720_01, who exhibited the highest pain value of 9.4. Due to the generally poor image quality in this subject's image set, data from subject 20100702_01 was not included in the statistical analysis.

Table 2.1 Subject Pain Level, Time Elapsed Since Injury, Injury State and Mean T_2 Time Evaluated by Bone for All Subjects

Subject Number	**Pain From Grip**	**Time From Injury to Scan (months)**	**Bone**	**Mean T_2 (ms)**	
				Normal Wrist	**Injured Wrist**
20100304_01	1/10	25	Radius	67	75*
			Lunate	63	65*
20100311_01	6/10	<1	Radius	59	140
			Lunate	56	136
20100416_01	2/10	≈22	Radius	53	83
			Lunate	65	84
20100702_01**	7.8/10	1	Radius	82	60
			Lunate	N/A	83
20100720_01	9.4/10	69	Radius	74	82
			Lunate	71	75
20100726_01	0/10	11	Radius	91	94
			Lunate	85	77
20100920_01	1.6/10	≈60	Radius	79	85
			Lunate	82	89

* Omitted 80 ms image set due to poor image quality
** Omitted from statistical analysis due to poor image quality

2.5 DISCUSSION

The injured wrist cartilage of each subject exhibiting unilateral scapholunate dissociation produced higher T_2 values than the contralateral, normal control wrist. A statistically significant increase in T_2 values was seen in the pooled data (radius and lunate data combined) between normal and injured wrist cartilage of all subjects. The significant relationship between the injured radius and injured lunate values indicate consistency in the study methods, as well as suggesting homogeneity in cartilage T_2 values of an injured wrist. These findings support the study hypothesis that cartilage in an injured wrist will exhibit higher T_2 values than cartilage in a normal wrist.

We used T_2 mapping because of its simplicity and ubiquity across scanners. Mosher et al. (9) reported that T_2 values of normal cartilage range from 15 ms to 60 ms, with variation in the T_2 values spatially related to different locations in the cartilage, which is comparable to the values found in the current study. The joint and location of the cartilage within the wrist that is selected in our study may affect the resulting T_2 values, as the wrist contains thin cartilage when compared to other joints. Dunn et al. (10) found significantly higher T_2 values in knee cartilage of subjects who have arthritis when compared to healthy subjects in all but one of the knee compartments analyzed. In that study healthy cartilage T_2 values ranged from 32.1-35.0 ms, and osteoarthritic cartilage T_2 values ranged from 34.4-41.0 ms. Although patients were divided into two OA groups in the study, mild and severe OA, no significant differences in T_2 values were seen between the two groups. This suggests that T_2 values may be able to delineate between healthy and disease cartilage, but once the cartilage degeneration process

commences the T2 value may not significantly change during different stages of osteoarthritis.

Although the bone-specific radius and lunate data only showed a trend in increasing T_2 relaxation time values from the normal and injured wrists, a power analysis ($p<0.05$ and 80% power) indicates that significance should be found with 10 subjects in each group (normal and injured) for the radius, and 17 subjects in each group for the lunate. Thus, continued testing on additional subjects should show significance for each bone.

Inflammation, which is associated with additional fluid surrounding the joint, due to the injury may be occurring in the wrist and may alter the results of the T_2 time calculation. The larger T_2 values calculated occurred in the subjects with the least amount of time elapsed from wrist injury to scanning and the highest pain levels. As seen in Table 2.1, pain level does appear to be in the upper half of the pain scale for only the recent injuries, with the exception of one subject who exhibited the highest pain value. This suggests that inflammation and pain may also be associated with higher T_2 values. A study examining T_2 values in the muscles of runners associated an increase in the value as a sign of inflammation/edema, however, they suggested there may be other possibilities as to the cause in the T_2 value increases, such as the muscle exhibiting adaptations in its structure (11).

This study had a number of limitations, including the limited number of subjects. The high amount of variability in the mean T_2 times is another limitation, and it may be due to a number of factors. Motion artifact is always present to some degree in the

images due to the nature of the human subject scans. Pixels may also experience some partial volume effects that could cause large changes in pixel intensity when exacerbated by motion. Error in the image registration may also lead to error in the mean T_2 times, similar to motion artifact. Examples of poor quality images were seen in the case of 20100304_01 injured, in which the 80 ms image data was discarded, as well as in subject 20100702_01, whose data was completely discarded from statistical analysis due to the poor image quality. Poor image quality refers to images with poor contrast, high amounts of noise in the cartilage regions, obvious motion artifact, and/or gross increases in image intensity as the echo time lengthens. In the future, improved hardware could aid in the reduction of motion related artifacts using multi-echo data acquisition per excitation. Scan time reduction and/or spatial resolution increase could be seen with hardware improvement to a multi-channel receiver coil array.

In conclusion, T_2 relaxation time consistently increases with injury to the wrist. T_2 relaxation time appears to be a promising indicator of cartilage degeneration in this wrist model, with higher values seen in injured wrists than normal wrists. Continued data collection and analysis with enrollment of additional subjects is ongoing, and is expected to reinforce these findings.

2.6 ACKNOWLEDGEMENTS

We would like to acknowledge support for the study from NIH, a graduate student fellowship from NSF, and technical assistance from Allan Schmitt of the University of Kansas Medical Center.

2.7 REFERENCES

1. Ferreres A, Garcia-Elias M, Plaza R. Long-term results of lunocapitate arthrodesis with scaphoid excision for SLAC and SNAC wrists. J Hand Surg Eur Vol. 2009; 34:603-608.
2. Atkinson LS, Baxley EG. Scapholunate dissociation. Am Fam Physician. 1994; 49:1845-1850.
3. Peterson B, Szabo RM. Carpal osteoarthrosis. Hand Clin. 2006; 22:517-528; abstract vii.
4. Schmitt R, Froehner S, Coblenz G, Christopoulos G. Carpal instability. Eur Radiol. 2006; 16:2161-2178.
5. Tanaka T, Ogino S, Yoshioka H. Ligamentous injuries of the wrist. Semin Musculoskelet Radiol. 2008; 12:359-377.
6. Blumenkrantz G, Majumdar S. Quantitative magnetic resonance imaging of articular cartilage in osteoarthritis. Eur Cell Mater. 2007; 13:76-86.
7. Gold GE, Beaulieu CF. Future of MR imaging of articular cartilage. Semin Musculoskelet Radiol. 2001; 5:313-327.
8. Borthakur A, Shapiro EM, Akella SV, Gougoutas A, Kneeland JB, Reddy R. Quantifying sodium in the human wrist in vivo by using MR imaging. Radiology. 2002; 224:598-602.
9. Mosher TJ, Dardzinski BJ. Cartilage MRI T2 relaxation time mapping: overview and applications. Semin Musculoskelet Radiol. 2004; 8:355-368.

10. Dunn TC, Lu Y, Jin H, Ries MD, Majumdar S. T2 relaxation time of cartilage at MR imaging: comparison with severity of knee osteoarthritis. Radiology. 2004; 232:592-598.

11. Marqueste T, Giannesini B, Fur YL, Cozzone PJ, Bendahan D. Comparative MRI analysis of T2 changes associated with single and repeated bouts of downhill running leading to eccentric-induced muscle damage. J Appl Physiol. 2008; 105:299-307.

3.0 MRI Evaluation of Surgical Effects on Wrist Cartilage with Scapholunate Ligament Injury

Dannica L. Sturgeon, BS[1]; Phil Lee, PhD[2,3]; Terence E. McIff, PhD[4]; E. Bruce Toby, MD[4],
Kenneth J. Fischer, PhD[1,4]

[1]Department of Mechanical Engineering, University of Kansas, Lawrence, KS, 66045, USA

[2]Hoglund Brain Imaging Center, University of Kansas Medical Center, Kansas City, KS, 66160, USA

[3]Department of Molecular & Integrative Physiology, University of Kansas Medical Center, Kansas City, KS, 66160, USA

[4]Department of Orthopedic Surgery, University of Kansas Medical Center, Kansas City, KS, 66160, USA

Kenneth J. Fischer, PhD

Learned Hall
1530 W. 15th St, Room 3138
Lawrence, KS 66045-7609, USA

785-864-2994 (telephone)

785-864-5254 (fax)

fischer@ku.edu

Running Title: T_2 of Wrist Cartilage Pre and Post Operation

Key words: articular cartilage, MRI, osteoarthritis, scapholunate dissociation, surgery, T_2 relaxation time

Funding and Grants: Study supported by NIH. Graduate fellow stipend supported by NSF.

For submission to the Journal of Hand Surgery

3.1 ABSTRACT

Purpose

The objective of this study was to non-invasively evaluate changes in the biophysical and biochemical status of the cartilage in the wrist following unilateral scapholunate ligament injury in the pre-operation and post-operation states by analyzing the T_2 relaxation time in the cartilage of human subjects.

Methods

A Siemens Allegra 3T scanner with a custom-built wrist coil was used to complete magnetic resonance imaging (MRI) scan sessions. Subjects attended scan sessions for both their injured wrist and contralateral (normal) wrist pre-operation and post-operation.

Results

The T_2 trends from all subjects show that the values increase from normal to injured wrist, when analyzing means by bone in the pre-operation and post-operation state. The trends continued when analyzing the means of the pooled data, combining the radius and lunate, with the differences between normal and injured wrist post-operation showing significance. Injured wrist means increased significantly from the pre-operation scan session to the post-operation scan session. Significance was also observed between the normal pre-operation T_2 values and the injured post-operation values.

Discussion

Our data indicates that T_2 values increase between the normal and injured cartilage state. The injured cartilage T_2 values continue remain elevated from the pre-operation to the post-operation scan sessions. Consistency in the results is indicated by the lack of any difference in the normal data sets between the pre-operation and post-operation scan sessions.

Clinical Relevance

The goal of this research is to aid in the assessment and treatment of wrist injuries, and to help prevent osteoarthritis resulting from injury.

3.2 INTRODUCTION

Surgery is very common, with multiple procedures performed every day across the nation. In the United States alone, 45 million inpatient procedures were performed in 2007 (1). Debilitating injuries to the hand and wrist are widespread; a regularly encountered injury is scapholunate dissociation. In general, the injury will progress to scapholunate advanced collapse (SLAC) if no treatment is received, which is associated with osteoarthritis of the wrist (2). Surgery aims to restore normal biomechanics to the wrist and alleviate the pain associated with the injury.

When a wrist injury occurs, the scapholunate interosseous ligament (SLL) is often affected (3). Common causes of injuries leading to scapholunate dissociation include falling on an outstretched hand (4), and repetitive motions that involve rotating the wrist (3). If the integrity of the scapholunate ligament is compromised, abnormal stresses are experienced on the surrounding articular surfaces as the scaphoid rotates and the scaphoid and lunate dissociate (3). The dorsal segment of the scapholunate ligament's rupture leads to scapholunate dissociation and rotatary subluxation of the scaphoid, as it is the primary stabilizing segment of the ligament (5). SLAC, scapholunate advanced collapse, can result from if the injury's severity continues to increase (6).

Although an injured SLL has a wide range of available treatments, surgery is often selected. Conservative options, such as immobilization of the wrist and medication to reduce inflammation, may be utilized in chronic cases of scapholunate dissociation. Active individuals who wish to resume normal activities often have difficulty obtaining successful results from these conservative treatments (3) and opt for surgery.

Magnetic resonance imaging (MRI) possesses many qualities, such as its non-invasive nature and the high quality images produced, that make it an effective way to assess cartilage, ligaments, and other soft tissues. Accomplishing direct imaging of ligaments without the use of any invasive procedures can only be accomplished through the use of MRI (3, 5). The benefits of MRI for monitoring arthritis have been stated by Blumenkrantz et al. (7), with its multi-planar and high spatial resolution images using no ionizing radiation to provide outstanding joint tissue images. Gold et al. claims MRI is the best assessment technique for visualizing injuries and repairs to cartilage due to the contrast it provides for soft tissues such as cartilage (8).

The objective of this study was to evaluate changes in the biophysical and biochemical status of cartilage in the wrist following scapholunate ligament injury in the pre-operation and post-operation (pre-op and post-op, respectively) states by analyzing the T_2 relaxation time in the cartilage of human subjects, with the goal of aiding in the assessment and treatment of wrist injuries and preventing osteoarthritis resulting from injury. Our first hypothesis was that the calculated T_2 values would be lower in the contralateral (uninjured) normal wrist than the injured wrist in both the pre-op and post-op states. Our second hypothesis was that even though surgical treatment may restore the wrist to a normal state of function, the calculated T_2 relaxation time would remain high in the cartilage of injured wrists post-op due to limited ability of the cartilage to repair itself.

3.3 METHODS

The study protocol was approved by the University of Kansas Medical Center's Human Subjects Committee. Magnetic resonance imaging (MRI) of radiocarpal joints was completed on each of three human subjects displaying unilateral scapholunate

dissociation in two sessions: pre-op and post-op. Before each scan session, information regarding the pain experienced by the subject in completing a grip strength task was collected and recorded. The subject reported pain associated with completing the task by marking where pain fell on a 0-10 visual-analog scale; zero correlated to experiencing no pain, and ten correlated to experiencing unbearable pain.

A Siemens Allegra 3T scanner (Siemens Medical Solutions USA, Inc., Malvern, PA) with a custom-built wrist coil was used for the MRI scans. To calculate the T_2 relaxation times of the cartilage in the wrist, it was necessary to complete a series of four spin echo scans (0.39 x 0.39 x 0.6 mm/pixel) with echo times of 20, 40, 60, and 80 ms during each subject scan session. Completion of the scan series collected 76 images (19 images/echo time). Imaging was completed and analyzed on both the injured and contralateral (normal) wrist in both the pre-op and post-op scan sessions, with the patient's wrists in a relaxed state. The normal wrist had no report of previous injury to the wrist.

Each MRI scan session resulted in four image sets that were co-registered to minimize the effects of any motion occurring throughout and between scans. Analyze (AnalyzeDirect, Inc., Overland Park, KS) was used to complete the co-registrations. A manually driven co-registration was first performed with the software before completing twenty-five automatic iterations of the automatic registration function built into the program. The final co-registration used in the analysis was selected after analyzing the magnitudes of image movement. The 60 ms image set was used to manually define the radiocarpal cartilage regions on the radius and lunate. Cartilage definition was completed using Adobe Photoshop Elements 8.0 (San Jose, CA). To avoid partial volume effects at

the edges of the cartilage as much as possible, only the center part of the cartilage was defined as cartilage in the template (Figure 3.1).

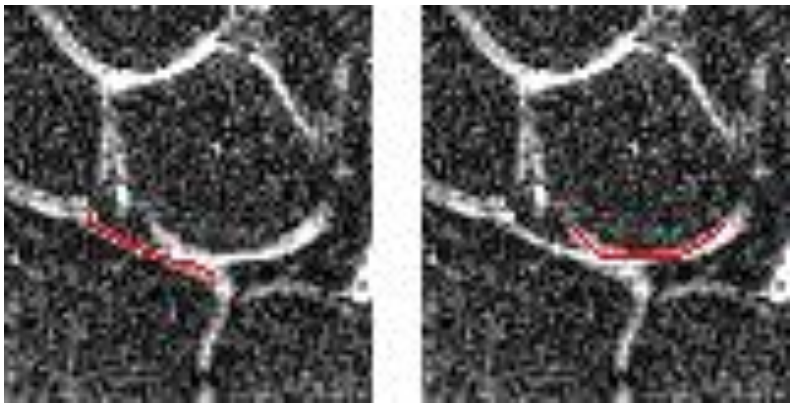

Figure 3.1 Cartilage template example image. The radius template is displayed on the left. The lunate cartilage template is displayed on the right. Image taken from the 60 ms image set (0.39 x 0.39 x 0.6 mm/pixel).

A custom Matlab code was then used to analyze the data and calculate the T_2 value for each cartilage pixel. The T_2 value was calculated through Matlab's linear regression to the semi-log plot of echo time vs. the natural logarithm of signal intensity attained from each of the four echo times (Figure 3.2). The governing equation, $S(TE) \propto e^{(-TE/T2)}$ with S being the signal acquired at the four different echo-times (TE) (7) was used to calculate the T_2 values. Data from the pixels was filtered in a three-step process. The first step filter was to dismiss the T_2 value from further analysis if the individual pixel regression produced a negative value. In the second step filter, pixels were discarded if the correlation coefficient (R^2 value) was below 0.6. Pixels from the entire bone template on each image were then analyzed, and pixels with outlier values outside the range of mean ± 3 standard deviations were iteratively omitted from further analysis until all outlier pixels had been identified for the third step filter. This procedure was

completed to reduce the spatial mismatch effect that could occur in the data due to movement of the wrist in the through-plane and/or the co-registration technique and resulted in an average of 26% of the original pixels defined as cartilage being evaluated in further statistical analysis.

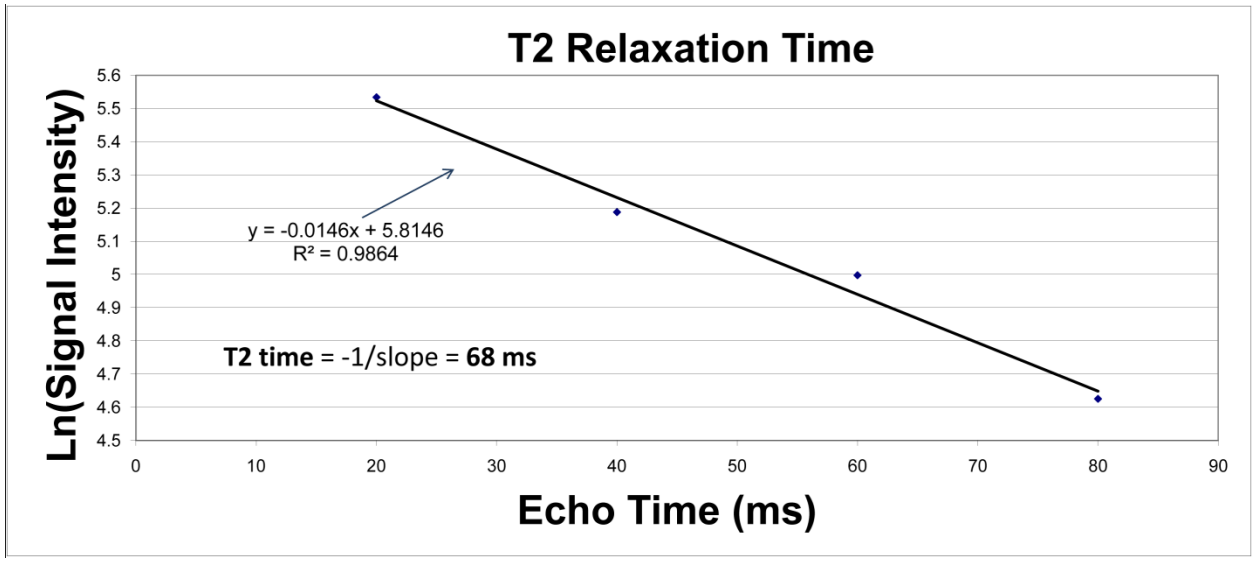

Figure 3.2 A plot of the echo time (ms) and the natural logarithm of the pixel signal intensity is used to calculate the T_2 relaxation time for each cartilage pixel. A linear fit of the four points is conducted; the T_2 value is the negative reciprocal of the line slope.

After successfully defining the pixels to be included in further analysis, the signal intensities from each echo time were analyzed, and the average signal intensity from each echo time was computed. The four averages were then used to calculate a single T_2 time for the template. The mean T_2 times and descriptive statistics for each bone were compared in the pre-op and post-op image sets between the normal and injured wrists, and between injured wrists in the pre-op and post-op images. The means were compared using repeated-measures ANOVA and Fisher's PLSD post-hoc analysis, with significance defined as $p<0.05$.

3.4 RESULTS

Results indicated a consistent trend for higher mean T_2 time for the injured wrist. For one subject, 20100304_01, the 80 ms image data was discarded due to gross inconsistencies in the pixel intensities in the images obtained from the scanner. For all subjects analyzed, the mean T_2 value was higher for the injured wrist than for the normal wrist in both the radius and the lunate cartilage (Table 3.1). The T_2 time trends from all subjects also indicated that a higher T_2 time is associated with an injured wrist when analyzing means by pooled wrist cartilage for both the pre-op and post-op case (Figure 3.3).

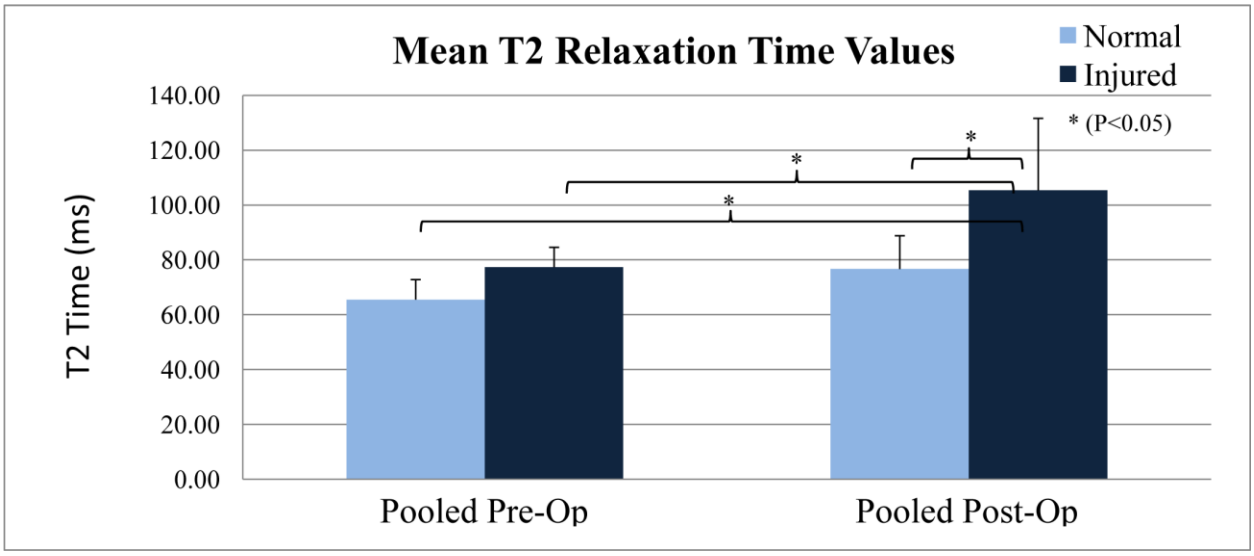

Figure 3.3 Mean T_2 values (+ 1 standard deviation) for control and injured wrist pooled data, pre-op and post-op.

Significant differences exist between injured pre-op and injured post-op T_2 values, as well as between normal and injured post-op wrists. The pre-op normal scan was also significantly different than the post-op injured wrist, as expected. These findings partially confirm the first study hypothesis, as the post-op wrists show a

significant difference between normal and injured wrists. The results support the second study hypothesis, as the T_2 times for injured wrists show increased values from pre-op to post-op.

Table 3.1 Subject Mean T_2 Time by Bone.

Subject Number	**Bone**	**Mean T_2 Normal (ms)**		**Mean T_2 Injured (ms)**	
		Pre-Op	**Post-Op**	**Pre-Op**	**Post-Op**
20100304_01	Radius	67	99	75*	155
	Lunate	63	79	65*	109
20100416_01	Radius	53	67	83	87
	Lunate	65	66	84	102
20100720_01	Radius	74	77	82	97
	Lunate	71	72	75	82

* Omitted 80 ms image set due to poor image quality

Pain reported from completing the grip test, along with the injured wrist grip strength and operative procedure performed, is shown with the injured T_2 values in Table 3.2. The pain does not appear to consistently correspond to the calculated T_2 values for the wrists. The pain remained the same or decreased for all cases presented after surgery. In subject 20100304_01 the pain remained the same for the post-op scan session from the pre-op scan session, while decreasing drastically in the other two subjects. The grip strength decreased post-surgery for two subjects, while increasing in subject

20100720_01. Three different types of surgery were performed; the approach for each subject was chosen according to the surgeon's assessment of the individuals.

Table 3.2 Subject Operative Method, Pain Level, and Injured Grip Strength.

Subject Number	**Operative Method**	**Injured Wrist Pain From Grip**		**Injured Wrist Grip Strength (lb)**	
		Pre-Op	**Post-Op**	**Pre-Op**	**Post-Op**
20100304_01	Direct Ligament Repair	1/10	1/10	130	115
20100416_01	Modified Brunelli Method	2/10	0.3/10	68	46
20100720_01	Scaphocapitate Fusion	9.4/10	0.5/10	37	51

3.5 DISCUSSION

Injured wrists in subjects exhibiting unilateral scapholunate dissociation pre-surgery and returned for a follow-up scan post-operation showed consistent trends for higher T_2 values. These trends were apparent when analyzing the data both by bone and by pooled data that combined the radius and lunate data to the general categories of normal and injured wrist cartilage. Significant differences were seen between the normal wrist pre-op and the injured wrist post-op, which is an expected result. The first hypothesis was partially supported by the significance between the normal and injured wrist post-op. Significance was also seen in the injured wrist between pre-op and post-

op, with higher values occurring post-op, which corresponded to the second hypothesis. No differences between the normal wrist pre-op and post-op were detected, indicating consistency in the methods, as stable values would be expected in control wrists. Pain, although remaining consistent for one subject from pre-op to post-op, dramatically decreased in the other two subjects following surgery. Grip strength tended to decrease post-op, with the exception of one subject who experienced a rise in grip strength.

When the SLL suffers damage, the motion and alignment of carpal bones are altered. Pain is generally experienced; over time osteoarthritis commonly develops (6). SLAC wrist is the most common cause (55% of cases) of wrist osteoarthritis (9). Although pain may be alleviated by surgery initially, as indicated in Table 3.1, we speculate that cartilage degeneration may not cease due to the limited ability for cartilage to repair itself. This position is supported by the prevalence of osteoarthritis surrounding this injury. In one study on anterior cruciate ligament (ACL)-reconstructed knees, no differences were initially found in T_2 values between injured and healthy knees. However, one year after surgery, subjects demonstrating lesions in a certain part of the meniscus showed a greater increase in T_2 values than other subjects failing to exhibit this type of injury (10). The continued increase in T_2 time seen in the injured wrist from pre-op to post-op suggests that cartilage may not always have the ability to repair itself following surgery.

The status of cartilage can be measured with T_2-weighted MRI. T_2 mapping tracks changes in the hydration and biochemical composition of the cartilage being imaged; changes in the status of these are indicators of cartilage degeneration. The T_2 of water in healthy cartilage is short because the water molecules are largely bound by the

collagen-proteoglycan matrix in the cartilage, with little motion occurring during the imaging process. As cartilage degeneration occurs, water escapes into the synovial fluid of the joint. The resulting T_2 values are higher because of the increased molecule mobility. Thus, as the matrix integrity is compromised and cartilage degeneration continues, the T_2 relaxation time of the cartilage increases (7).

The simplicity in attaining high quality images, and it's commonality among scanners, made T_2 mapping an excellent choice for this study. Normal values of cartilage have previously been reported as ranging between 15 and 60 ms (11), which is comparable to the values attained in this study. The paper also stated that T_2 values are spatially related to the location in the cartilage (11). The spatial variation may explain some of the variability in our study, as the wrist joint contains very thin cartilage compared to other joints in the body. A study examining the knee found arthritic cartilage to have higher T_2 values than healthy cartilage (12). The T_2 values found in that study ranged from 32.1-35.0 ms for the healthy cartilage, and from 34.4-41.0 ms for the degenerating cartilage. These results suggest that T_2 values are useful in determining whether the cartilage is healthy or not, as differences were only noticed in the T_2 values of cartilage between healthy and OA, not between differing severities of OA. This is supported by a study comparing the T_2 values of the patellar cartilage in knees with OA, where no correlations were found between stages of OA and the T_2 value attained (13).

Inflammation due to the injury may be occurring in the wrist. The largest T_2 values calculated occurred in the subject's post-op scans. Although these sessions were performed approximately twelve weeks after surgery, inflammation from the surgery could still be altering calculated T_2 values.

One limitation of this study was variability in T_2 values. The variability is likely due to a combination of factors, including motion artifact and partial volume effects in pixels, especially when any motion occurs. Co-registration error can impact the results in similar fashion to motion artifact, and may alter resulting T_2 values. Future improvements to the study could include enrollment of additional subjects, as well as improved hardware. Multi-echo data acquisition per excitation could help reduce any motion artifacts seen in the images, and spatial resolution could be increased and/or scan time reduces if the hardware was upgraded to a multi-channel receiver coil array.

This study only included three subjects, each of whom underwent a different type of surgery for their scapholunate dissociation. The scaphocapitate fusion and direct ligament repair subjects experienced a slight decrease in grip strength post-op, with pain remaining the same or decreasing. The subject treated with the modified Brunneli experienced an increase in grip strength post-op, although the high level of pain pre-operation could have interfered with the gripping ability of the subject during the pre-op assessment. Although potential differences can be observed in the data, the low number of subjects in this study prevents any comparisons between surgical methods from being conducted; rather, the current study focuses on how surgery affects T_2 values attained from injured wrist cartilage.

In conclusion, T_2 relaxation time does appear to indicate changes in cartilage due to injury in this surgical repair wrist model. Higher values were seen in injured wrists than normal wrists both pre-operatively due to changes from injury and post-operatively, and higher calculated T_2 values in injured wrists after surgery than pre-operation, possibly due to additional changes from surgery. Continued data collection and analysis

with enrollment of additional subjects is ongoing and is expected to reinforce these findings.

3.6 ACKNOWLEDGEMENTS

We would like to acknowledge support for the study from NIH, a graduate student fellowship from NSF, and technical assistance from Allan Schmitt of the University of Kansas Medical Center.

3.7 REFERENCES

1. Hall MJ, DeFrances CJ, Williams SN, Golosinskiy A, Schwartzman A. National Hospital Discharge Survey: 2007 summary. Natl Health Stat Report. 2010:1-20, 24.
2. Ferreres A, Garcia-Elias M, Plaza R. Long-term results of lunocapitate arthrodesis with scaphoid excision for SLAC and SNAC wrists. J Hand Surg Eur Vol. 2009; 34:603-608.
3. Atkinson LS, Baxley EG. Scapholunate dissociation. Am Fam Physician. 1994; 49:1845-1850.
4. Peterson B, Szabo RM. Carpal osteoarthrosis. Hand Clin. 2006; 22:517-528; abstract vii.
5. Schmitt R, Froehner S, Coblenz G, Christopoulos G. Carpal instability. Eur Radiol. 2006; 16:2161-2178.
6. Tanaka T, Ogino S, Yoshioka H. Ligamentous injuries of the wrist. Semin Musculoskelet Radiol. 2008; 12:359-377.
7. Blumenkrantz G, Majumdar S. Quantitative magnetic resonance imaging of articular cartilage in osteoarthritis. Eur Cell Mater. 2007; 13:76-86.
8. Gold GE, Beaulieu CF. Future of MR imaging of articular cartilage. Semin Musculoskelet Radiol. 2001; 5:313-327.
9. Feydy A, Pluot E, Guerini H, Drape JL. Osteoarthritis of the wrist and hand, and spine. Radiol Clin North Am. 2009; 47:723-759.
10. Li X, Kuo D, Theologis A, Carballido-Gamio J, Stehling C, Link TM, Ma CB, Majumdar S. Cartilage in anterior cruciate ligament-reconstructed knees: MR

imaging T1{rho} and T2--initial experience with 1-year follow-up. Radiology. 2011; 258:505-514.

11. Mosher TJ, Dardzinski BJ. Cartilage MRI T2 relaxation time mapping: overview and applications. Semin Musculoskelet Radiol. 2004; 8:355-368.

12. Dunn TC, Lu Y, Jin H, Ries MD, Majumdar S. T2 relaxation time of cartilage at MR imaging: comparison with severity of knee osteoarthritis. Radiology. 2004; 232:592-598.

13. Koff MF, Amrami KK, Kaufman KR. Clinical evaluation of T2 values of patellar cartilage in patients with osteoarthritis. Osteoarthritis Cartilage. 2007; 15:198-204.

4.0 OVERALL DISCUSSION AND FUTURE WORK

In these studies, the transverse relaxation time, T_2, of wrist cartilage in subjects exhibiting unilateral scapholunate dissociation was analyzed. Data was collected from seven subjects in the pre-operative state. Three of these subjects returned post-operation for a follow-up scan session at an average of twelve weeks following surgery. A Siemens Allegra 3T scanner (Siemens Medical Solutions USA, Inc., Malvern, PA) and a custom-built wrist coil was used for data collection. Four spin echo scans were completed to calculate the T2 relaxation time, with echo times of 20, 40, 60, and 80 ms. The non-invasive nature of T_2 imaging made it an effective way to gain information regarding the biophysical and biochemical status of the cartilage. The cartilage was evaluated with the goal of developing the ability to help treat injuries to the wrist, and prevent the osteoarthritis that often results from injuries.

The T_2 relaxation time in the pre-operative cases appears to be a promising indicator of cartilage degeneration. The values seen in the injured wrists were significantly higher than the T_2 values in the normal wrists for the pooled data (radius and lunate data combined); supporting the hypothesis that injured wrist cartilage will display higher T_2 values than normal cartilage. For all individual subjects and bones, a consistent trend towards increasing T_2 values in the injured wrist was present. A relationship between the means of the injured lunate and injured radius was detected, indicating homogeneity in the cartilage of injured wrists and consistency in the evaluation methods.

The subjects who returned for a follow-up scan post-operation provided additional information regarding the T_2 relaxation time trends present in the wrist cartilage. The

trend of increased T_2 values was seen in this analysis as well. For each subject analyzed, the T_2 value of the injured cartilage was greater than the T_2 value of the normal cartilage, in both the individual bone assessment and the pooled data assessment. Normal pre-operation wrists were found to be significantly different than injured post-operation wrists, which was an expected result. The post-operation wrists showed a statistically significant increase from the normal to injured wrist cartilage, which partially supports the hypothesis that the injured wrists will display a higher T_2 value than normal wrists in all cases. A significant difference was also seen between the pre-operation and post-operation injured wrists, which supports the hypothesis that the T_2 value of the injured cartilage would continue to remain high due to the lack of repair ability of the cartilage. No differences were detected between the normal wrist T_2 values between the pre-operation and post-operation, indicating consistency in the methods, as stable T_2 values would be expected in normal cartilage.

Information regarding the pain experienced by the subject during a grip test, as well as the time elapsed since injury to pre-operation scan was collected during the studies as well. Although no significant correlations have been identified, the pain level appears generally related to the time elapsed since injury in the pre-operation subjects. The surgery was successful in alleviating the pain resulting from completing a grip test in general. One subject experienced very low pain levels due to the grip test before surgery, and maintained the same pain level following surgery as well. No correlations with T_2 values were apparent for either the pain resulting from the grip test or the elapsed time from injury to scan time.

These studies had a number of limitations, including the low number of subjects analyzed. Although promising results have been obtained from the subjects analyzed to date, enrollment of additional subjects will continue to reinforce the significance of the findings. The cartilage in the wrist is much thinner than the articular cartilage found in other joints in the body. Identifying full pixels of cartilage can sometime be difficult with such thin cartilage on the radius and lunate. The location in the wrist that the cartilage is identified may affect the T_2 values attained, as cartilage location on each bone was not specified in the study methods. To date, the study makes no correlation to the stage of disease and T_2 values, other than the fact that the subjects have been diagnosed with scapholunate dissociation prior to participating in the study. The increase in T_2 values post-operation from the pre-operation state suggest that there may be a relation corresponding severity of injury to T_2 value, rather than just delineating between healthy and injured cartilage.

Inflammation, associated with additional fluid surrounding the joint of interest, may be occurring in the wrists we are imaging. Whether the cause of inflammation is the injury itself, or is a lasting effect of the surgery, the resulting T_2 values may be affected by the presence of inflammation in the joint.

Due to the nature of completing non-sedated human subject scans, motion artifact to some degree is always present. Partial volume effects, especially when exacerbated by motion, may also be experienced by the pixels identified in the thin wrist cartilage. Any errors in the co-registrations of the four image sets may also lead to errors in the mean T_2 times, causing effects similar to that of motion artifact in the images.

Future improvements to the hardware used for scanning could greatly improve the image quality attained from the scan sessions. Using multi-echo data acquisition per excitation could aid in reducing the motion artifact currently experienced during scanning. The required scan time could be reduced and/or the spatial resolution of the images increased if the hardware is upgraded to a multi-channel receiver coil array. Reducing scan time would also aid in the reduction of motion, as the subject would not be required to remain still for as long as they are currently required to.

The results attained from these studies provide many promising results that can be built upon and added to in the future. With additional subjects, the significance of the trends we are finding can be solidified, as well as new trends and correlations potentially identified.