

Imaging Modalities for the Glenoid Track in Recurrent Shoulder Instability

A Systematic Review

Matthew L. Vopat,^{*} MD, Christina A. Hermanns,^{†‡} BS, Kaare S. Midtgaard,^{§||¶} MD, Jordan Baker,[†] BS, Reed G. Coda,[†] BS, Sana G. Cheema,[†] BA, Armin Tarakemeh,[†] BA, Liam Peebles,[§] BA, Bryan G. Vopat,[†] MD, and Matthew T. Provencher,^{§||} MD

Investigation performed at the University of Kansas School of Medicine, Kansas City, Kansas, USA

Background: The glenoid track (GT) concept illustrates how the degree of glenoid bone loss and humeral bone loss in the glenohumeral joint can guide further treatment in a patient with anterior instability. The importance of determining which lesions are at risk for recurrent instability involves imaging of the glenohumeral joint, but no studies have determined which type of imaging is the most appropriate.

Purpose/Hypothesis: The purpose of this study was to determine the validity and accuracy of different imaging modalities for measuring the GT in shoulders with recurrent anterior instability. We hypothesized that 3-dimensional computed tomography (3D-CT) would be the most accurate imaging technique.

Study Design: Systematic review; Level of evidence, 4.

Methods: A systematic review was performed according to the PRISMA (Preferred Reporting Items for Systematic Reviews and Meta-Analyses) guidelines using PubMed, Scopus, Medline, and Cochrane libraries between database inception and July 2019. We included all clinical trials or cadaveric studies that evaluated imaging modalities for assessing the GT.

Results: A total of 13 studies were included in this review: 1 study using 2-dimensional CT, 6 studies using 3D-CT, 4 studies using magnetic resonance imaging (MRI), 1 study using magnetic resonance arthrography (MRA)/MRI, and 1 study combining CT and MRI. The mean sensitivity, specificity, and accuracy for 2D-CT was 92%, 100%, and 96%, respectively. For MRI, the means were 72.2%, 87.9%, and 84.2%, respectively. No papers included 3D-CT metrics. The mean intraclass correlation coefficients (ICCs) for intraobserver reliability were 0.9046 for 3D-CT and 0.867 for MRI. ICCs for interobserver reliability were 0.8164, 0.8845, and 0.43 for 3D-CT, MRI, and MRA/MRI, respectively.

Conclusion: There is evidence to support the use of both CT and MRI imaging modalities in assessing the GT. In addition, few studies have compared radiographic measurements with a gold standard, and even fewer have looked at the GT concept as a predictor of outcomes. Thus, future studies are needed to further evaluate which imaging modality is the most accurate to assess the GT.

Keywords: shoulder; glenoid labrum; instability; imaging and radiology; computed tomography; magnetic resonance

Anterior shoulder instability is a common problem in the general population, with even higher rates of incidence in at-risk populations, such as young males, collision sports athletes, and military personnel.¹² These populations are at an increased risk of morbidity because they are at a higher risk for recurrent glenohumeral instability. Major factors for recurrent glenohumeral instability are both glenoid bone loss (GBL) and humeral bone loss, also known as a Hill-Sachs lesion (HSL). It has been found that >90% of

patients with recurrent glenohumeral instability have GBL and 93% have HSL.^{2,3}

The glenoid track (GT) concept was first introduced by Yamamoto et al²⁹ as a way to evaluate these bony defects of the humeral head and the glenoid to help determine the type of HSL. This first illustrated how the degree of bone loss in the glenohumeral joint can guide further treatment in a patient with anterior instability.²⁶ An engaging HSL, or off-track lesion, is one in which the width is greater than the width of the GT, while a nonengaging, or on-track HSL, is one in which the width is less than the width of the GT (Figure 1).⁹ It is important to determine if an HSL is an off-track lesion, as it may be a predictor for recurrent instability even after arthroscopic Bankart repair.²⁷

The Orthopaedic Journal of Sports Medicine, 9(6), 23259671211006750
DOI: 10.1177/23259671211006750
© The Author(s) 2021

This open-access article is published and distributed under the Creative Commons Attribution - NonCommercial - No Derivatives License (<https://creativecommons.org/licenses/by-nc-nd/4.0/>), which permits the noncommercial use, distribution, and reproduction of the article in any medium, provided the original author and source are credited. You may not alter, transform, or build upon this article without the permission of the Author(s). For article reuse guidelines, please visit SAGE's website at <http://www.sagepub.com/journals-permissions>.

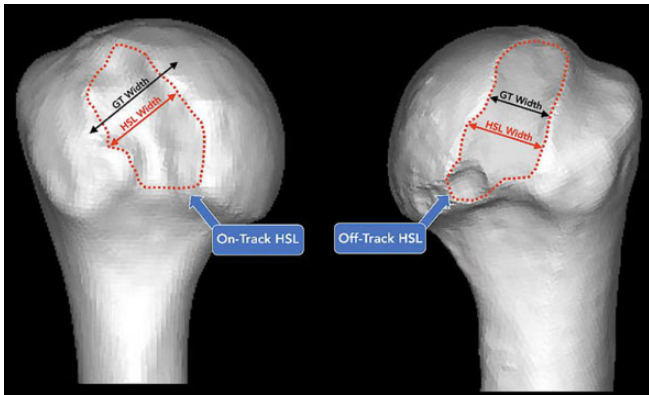


Figure 1. An HSL is considered on-track if the lesion width is less than the width of the GT. An HSL is considered off-track if the lesion width is greater than the GT width. GT, glenoid track; HSL, Hill-Sachs lesion. (From Di Giacomo G, Itoi E, Burkhart SS. Evolving concept of bipolar bone loss and the Hill-Sachs lesion: from “engaging/nonengaging” lesion to “on-track/off-track” lesion. *Arthroscopy*. 2014;30(1):90-98. Copyright 2014. Reprinted with permission from Elsevier).⁹

Di Giacomo et al⁹ developed an algorithm for treating anterior instability via the GT concept using the percentage of the glenoid defect along with the on- or off-track nature of the HSL to determine if a patient was a candidate for arthroscopic Bankart repair, with or without remplissage, versus a Latarjet procedure, with or without a humeral bone graft, or remplissage versus additional procedures. The algorithm categorized patients into groups 1 to 4 to determine treatment: group 1 patients had a glenoid defect <25% and an on-track HSL and received arthroscopic Bankart repair; group 2 had a glenoid defect <25% with off-track HSL and received arthroscopic Bankart repair with remplissage; group 3 had a glenoid defect >25% with on-track HSL and received the Latarjet procedure; and group 4 had a glenoid defect >25% with off-track HSL and received the Latarjet procedure, with or without a humeral-sided procedure after the Latarjet procedure.⁹

To use the GT concept to appropriately diagnose the severity of a shoulder's instability, the best imaging modality for quantifying glenohumeral bone loss must first be evaluated. Radiography, computed tomography (CT), and magnetic resonance imaging (MRI) can all be used to diagnose a humeral bone defect.¹⁰ However, CT imaging has

become the gold standard to determine the severity of an HSL, while MRI is the superior method for assessing soft tissue anatomy of the glenohumeral joint.¹⁰ Three-dimensional (3D)-CT is thought to give a more accurate measurement of humeral bone defects because of improved conceptualization,^{1,10,17} but it necessitates increased radiation exposure.²⁶ MRI can be used to measure bone loss, but ultimately 2-dimensional (2D)-MRI measurements may still overall be a poor predictor of bone loss^{25,26}; 3D-MRI can be performed and may be a future potential imaging technique for the GT.⁶

A scoping review by Saliken et al²⁶ summarized current studies on imaging and calculation of bone loss and prediction of recurrent instability. They concluded that CT was the most accurate method to measure bone loss; however, they did not focus specifically on the GT concept. Furthermore, it is essential for a physician to know what imaging modalities are reliable in quantifying these bipolar lesions of the GT to properly care for patients with anterior shoulder instability. Thus, the purpose of this systematic review was to determine the reliability of using the GT concept in different imaging modalities to determine the on- or off-track nature of a shoulder with recurrent instability. Following the results of the Saliken et al review, we hypothesized that CT would be the most accurate method to measure the GT.

METHODS

Search Strategy and Study Selection

This study followed the PRISMA (Preferred Reporting Items for Systematic Review and Meta-Analyses) statement guidelines. A literature review was conducted using the PubMed, Scopus, Medline, and Cochrane libraries databases. The search results included papers between database inception and July 2019. The search was conducted using the terms “Imaging” OR “Radiographic” OR “CT” OR “Computed Tomography” OR “MRI” OR “Magnetic Resonance Imaging” AND “Hill Sachs” OR “Glenoid Bone Loss” OR “Humeral Head Bone Loss” OR “Shoulder Instability” OR “On Track” OR “Off Track” OR “Bi-Polar” OR “Bone Loss” OR “Glenoid Track” OR “Engaging Lesion” OR “Non-engaging Lesion.” Two investigators (C.A.H. and M.L.V.) excluded duplicates and excluded papers based on titles and abstracts. For the full-text articles, the same 2 investigators excluded full texts that did not match

†Address correspondence to Christina A. Hermanns, BS, 5145 Birch Street, Roeland Park, KS 66205, USA (email: chermanns@kumc.edu).

*University of Kansas School of Medicine–Wichita, Wichita, Kansas, USA.

†University of Kansas School of Medicine–Kansas City, Kansas City, Kansas, USA.

§Steadman Philippon Research Institute, Vail, Colorado, USA.

||The Steadman Clinic, Vail, Colorado, USA.

¶Division of Orthopaedic Surgery, Oslo University Hospital, Oslo, Norway.

Final revision submitted February 17, 2021; accepted February 28, 2021.

One or more of the authors has declared the following potential conflict of interest or source of funding: M.L.V. has received education payments from Titan Surgical Group and hospitality payments from DePuy and Zimmer Biomet. B.G.V. has received education payments from Titan Surgical Group, consulting fees from DePuy, and hospitality payments from Smith & Nephew. M.T.P. has received consulting fees from Arthrex and JRF, nonconsulting fees from Arthrex and ArthroSurface, honoraria from Flexion and JRF, and royalties from Arthrex and ArthroSurface. AOSSM checks author disclosures against the Open Payments Database (OPD). AOSSM has not conducted an independent investigation on the OPD and disclaims any liability or responsibility relating thereto.

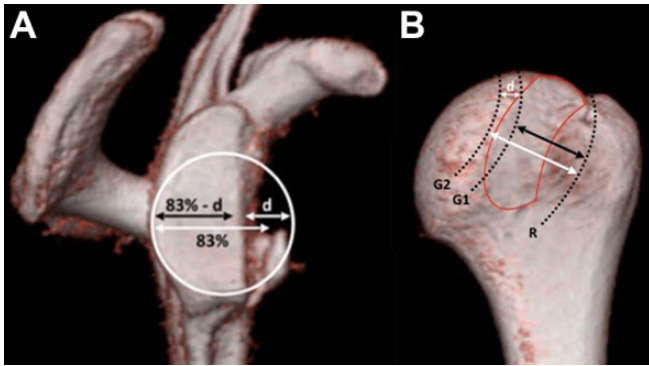


Figure 2. (A) GT measured by the following equation: $(0.83 \times \text{normal glenoid width}) - d$, where d is the width of bone loss. This is represented by the black arrow. The white arrow represents the 83% of the normal glenoid width. (B) R represents the medial margin of the rotator cuff attachment, $G1$ represents the location of a medial margin of the GT, and $G2$ represents the location of the medial margin of the GT without any bone loss. The red outline refers to the borders of the GT. GT, glenoid track. (From Di Giacomo G, Itoi E, Burkhart SS. Evolving concept of bipolar bone loss and the Hill-Sachs lesion: from “engaging/nonengaging” lesion to “on-track/off-track” lesion. *Arthroscopy*. 2014;30(1):90-98. Copyright 2014. Reprinted with permission from Elsevier).⁹

eligibility criteria. A third investigator (B.G.V.) was consulted if there were any discrepancies between the 2 other investigators.

Eligibility Criteria

Eligible studies included both clinical trials and cadaveric studies published in the English language with at least 1 of the following measures assessing imaging modalities for the GT: accuracy, reliability, clinical predictive power, sensitivity, specificity, negative predictive value, positive predictive value (PPV), intraobserver reliability, and interobserver reliability. Exclusion criteria included animal studies, studies in a non-English language, or imaging studies without at least 1 of the statistical measures listed above. The most common way that the GT was measured was by 83% of the normal glenoid width minus the width of bone loss²⁵ (Figure 2); however, studies that measured GT using 84% or other methods listed in Table 1 were still included.

Data Extraction and Quality Approval

Studies were categorized based on the imaging modalities they included with measurements. The imaging modality used in the study, the number of investigators who took measurements for the study, and the number of shoulders included were recorded for each study. The technique by which the studies measured the GT and determined

whether it was engaging or nonengaging was also recorded. The studies were split up by imaging modality into groups for CT studies, MRI studies, and those that included both CT and MRI. The results of each study were recorded and summarized.

Quality Bias Assessment

Assessment of methodologic quality was conducted using the Cochrane Collaboration tool.¹⁴ Two authors (C.A.H., M.L.V.) evaluated studies for potential risk of bias by creating a bias table assessing the risk for selection bias, performance bias, detection bias, attrition bias, reporting bias, and any other sources of potential bias. If there was any discrepancy, a third investigator (B.G.V.) was consulted for the final decision.

Statistical Analysis

Descriptive statistics were calculated for each study, and parameters were analyzed. For each variable recorded, the number and percentage of studies that evaluated these measures were calculated.

RESULTS

The initial database search identified 2520 articles. Ultimately, 13 studies were included in the final qualitative synthesis. A diagram of the study selection process can be seen in Figure 3. Included were 1 study using 2D-CT,³ 6 studies using 3D-CT,^{4,5,8,11,20,27} 4 studies using MRI,^{13,16,18,28} 1 study using magnetic resonance arthrography (MRA) and MRI,²¹ and 1 study combining CT and MRI.¹⁹ Included in the quantitative analysis were 1 study utilizing 2D-CT,³ 1 using 3D-CT,¹¹ and 1 MRI study.¹³ All included articles were clinical studies except for Burns et al,³ which was a cadaveric study. A total of 1023 shoulders were included among the 13 studies, with 1011 shoulders from clinical studies on patients with shoulder instability and 12 from a cadaveric study. Table 1 summarizes the studies included in the systematic review.

Diagnosing On- and Off-Track HSLs

A summary of the reliability data according to imaging modality is shown in Table 2.

Two-Dimensional CT. Burns et al³ analyzed the GT concept using 2D-CT. Using a cadaveric model, they created both HSLs and glenoid lesions of varying sizes. The calculation used to measure the GT was 84% of glenoid width minus GBL, the same equation as originally described by Di Giacomo et al.⁹ $HSL > GT$ was considered off-track and $HSL < GT$ was considered on-track. They reported a sensitivity of 92%, specificity of 100%, accuracy of 96%, and interobserver reliability of $\kappa = 1$ (Table 2).

Three-Dimensional CT. A total of 6 studies^{4,5,8,11,20,27} measuring on- or off-track lesions using 3D-CT as the imaging modality were included. Of those, 2 studies^{8,11} measured the GT via the original equation of Di Giacomo

TABLE 1
Summary of Studies Included in Analysis (N = 13 studies; 1023 shoulders)^a

Lead Author, y	Shoulders, n	Examiners, n	Imaging Modality	Measurement of GT	Outcomes Measured	Arthroscopic Engaging/ Nonengaging Technique
Burns, ³ 2016	12	2	2D-CT	83% of glenoid width minus GBL	SPE, SEN, ACC, INTER	HSL created on cadaveric shoulders and measured before imaging
Cho, ⁴ 2011	107	1	3D-CT	Distance between the center of HSL and lateral margin of greater tuberosity	Mann-Whitney <i>U</i> , INTER, INTRA	Defined HSL in which long axis of defect was parallel to anterior glenoid and engaged in anterior glenoid rim during arthroscopic examination as engaging
Clement, ⁵ 2017	46	2	3D-CT	Glenoid coordinate system was used to determine axis of defect as described by Ohl et al ²²	INTER, INTRA	Compared with average locked positions and functional WOSI and QuickDASH scores
Di Giacomo, ⁸ 2016	102	2	3D-CT	83% of glenoid width minus GBL	INTER, INTRA	Used 3D reconstruction of CT scan. Considered HSL located within the GT to be on-track lesions
Funakoshi, ¹¹ 2019	16	1	3D-CT	83% of glenoid width minus GBL	Cohen agreement between 2 methods	Arthroscopy recorded bone loss measurements. On-track lesions: HSL < GT
Matsumura, ²⁰ 2017	180	2	3D-CT	Used 3D reconstructions of CT scans to measure: length = long axis; width = short axis	INTER, INTRA	—
Schneider, ²⁷ 2017	71	4	3D-CT	Used methods of Di Giacomo et al ⁷	INTER, INTRA	—
Gyftopoulos, ¹³ 2015	76	2	MRI	83% of glenoid width minus GBL	SEN, SPE, ACC, PPV, NPV, INTER, INTRA	Evaluation for engagement performed during arthroscopic evaluation before repair. HSL was considered engaging if long axis became parallel and in contact with anterior glenoid in 90° abducted and externally rotated plane
Kawakami, ¹⁶ 2019	41	2	MRI	Used methods of Omori et al ²³	Pearson correlation, INTER, INTRA	—
Lau, ¹⁸ 2017	75	2	MRI	84% of glenoid width minus GBL	Odds ratio, <i>t</i> test, INTER, INTRA	—
Shaha, ²⁸ 2016	57	2	MRI	83% of glenoid width minus GBL	INTER, INTRA	Outcomes assessed according to shoulder stability on examination and subjective outcome
Metzger, ²¹ 2013	140	3	MRA/MRI	84% of glenoid width minus GBL	Mean bone loss, INTER	Followed method of Burkhart and De Beer ² to document humeral head engagement during arthroscopy
Locher, ¹⁹ 2016	100	1	CT, MRI	83% of glenoid width minus GBL	Odds ratio, recurrence rate of instability	Diagnostic arthroscopy of type and direction of shoulder instability was performed. Used methods of Di Giacomo et al ⁹ to determine on- or off-track

^aDashes indicate that the paper did not include this information. 2D, 2-dimensional; 3D, 3-dimensional; ACC, accuracy; CT, computed tomography; GBL, glenoid bone loss; GT, glenoid track; HSL, Hill-Sachs lesion; INTER, interobserver reliability; INTRA, intraobserver reliability; MRA, magnetic resonance arthrography; MRI, magnetic resonance imaging; NPV, negative predictive value; PPV, positive predictive value; QuickDASH, shortened version of Disabilities of the Arm, Shoulder and Hand; SEN, sensitivity; SPE, specificity; WOSI, Western Ontario Shoulder Instability Index.

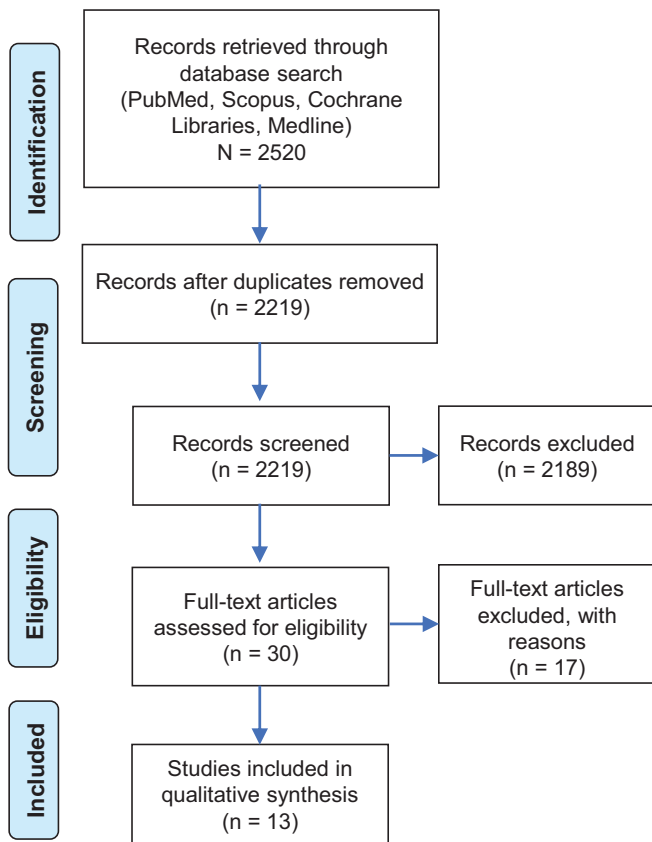


Figure 3. PRISMA (Preferred Reporting Items for Systematic Reviews and Meta-Analyses) flow diagram outlining the process of selecting papers included in this study.

et al,⁹ 1 study⁴ measured GT distance as the distance between the center of the HSL and the lateral margin of greater tuberosity, and 3 studies^{5,20,27} did not specify their technique. When determining on- versus off-track lesions, the studies had variable techniques. Funakoshi et al¹¹ illustrated that HSL > GT was off-track and HSL < GT was on-track. Di Giacomo et al⁸ demonstrated that if the HSL was located within the GT, it was considered on-track, while if it extended past the medial margin of the GT, it was off-track. Cho et al⁴ determined that HSL lesions parallel to the anterior glenoid and engaged in the glenoid rim were considered off-track lesions. Three studies^{5,20,27} did not specify how to determine on- versus off-track lesions.

Of the 6 3D-CT studies, 5 reported intraobserver and interobserver reliabilities.^{4,5,8,20,27} The range of intraobserver reliability within the CT studies was 0.688 to 0.999, with a mean of 0.9046. The range of interobserver reliability within the CT studies was 0.409 to 0.999, with a mean of 0.8164. No studies reported sensitivity, specificity, or accuracy of the GT concept using 3D-CT, but 1 study¹¹ did report the number of correctly identified off-track shoulders (10/16 shoulders).

Magnetic Resonance Imaging. A total of 4 studies^{13,16,18,28} included measuring on- or off-track lesions using MRI as the imaging modality. Of those, 2 studies^{13,28}

measured the GT using the original equation of Di Giacomo,⁹ 1 study¹⁸ measured the GT as 84% of glenoid width minus GBL, and 1 study¹⁶ measured the GT width by the distance from the anterior rim of the glenoid to the medial margin. To determine on- versus off-track lesions, 3 of the studies^{13,18,28} determined HSL > GT to be off-track and HSL < GT to be on-track. One study¹⁶ did not specify its technique to determine on- or off-track HSLs.

All 4 MRI studies provided both intra- and interobserver reliabilities.^{13,16,18,28} The range of intraobserver reliability within the MRI studies was 0.73 to 0.988, with a mean of 0.867. The range of interobserver reliability within the MRI studies was 0.81 to 0.988, with a mean of 0.8845. Only 1 MRI study¹³ reported sensitivity, specificity, accuracy, negative predictive values, and PPV of 91.1% and 65%, respectively. The gold standard for accuracy was the findings during patients' shoulder arthroscopy.

MRA/MRI. One study²¹ included both MRA and MRI measurements in its results. It determined the GT as 84% of glenoid width minus GBL and considered HSL > GT as off-track and HSL < GT as on-track. It included an interobserver reliability of $\kappa = 0.43$ for using MRA/MRI in detecting on- and off-track lesions.

CT and MRI. One study¹⁹ included both CT and MRI measurements in its results. It determined the GT as 83% of glenoid width minus GBL. HSL > GT was considered off-track, and HSL < GT was considered on-track. It did not include intra- or interobserver reliability or sensitivity or specificity, but instead it included an odds ratio of 8.3, indicating that off-track lesions result in a higher revision surgery rate.¹⁹

Quantitative Bias Analysis

The results of the assessment of methodologic quality using the Cochrane Collaboration tool are presented in Figure 4.¹⁴ The quantitative statistical analysis (meta-analysis) was unable to be performed because of the small numbers of papers reporting similar statistics, thereby creating a high risk of bias for a quantitative analysis.

DISCUSSION

The principal findings of this study demonstrated that the GT method can be used in 2D-CT, 3D-CT, MRA, and MRI images of shoulders with recurrent instability; however, only 2 studies looked at the accuracy of the GT measurement.^{3,13} Although other studies reported reliability, without accuracy, it is difficult to draw conclusions on the best imaging modality. Of papers that reported accuracy, a 2D-CT study by Burns et al³ reported a 96% accuracy, while an MRI study by Gyftopoulos et al¹³ reported an 84.2% accuracy. No 3D-CT paper included in this study reported accuracy. Although 3D-CT had a higher average intraobserver reliability than did MRI, the average interobserver reliability was higher for MRI than for 3D-CT. Thus, currently, 2D-CT was found to have the highest reported interobserver reliability in the current published literature. However, this systematic review illustrates that no study could

TABLE 2
Reliability of Determining if an HSL Is On- or Off-Track With Various Imaging Modalities^a

Lead Author, y	SEN, %	SPE, %	ACC, %	PPV	NPV	INTRA	INTER
2D-CT							
Burns, ³ 2016 (ABER) ^b	92	100	96	—	—	—	κ = 1
Burns, ³ 2016 (IAAA) ^b	92	81	87	—	—	—	ICC = 0.73
3D-CT							
Cho, ⁴ 2011	—	—	—	—	—	ICC = 0.916, 0.999	ICC = 0.772, 0.996
Clement, ⁵ 2017	—	—	—	—	—	ICC = 0.915, 0.94, 0.9, 0.895, 0.688, 0.977	ICC = 0.842, 0.81, 0.751, 0.848, 0.409, 0.947
Di Giacomo, ⁸ 2016	—	—	—	—	—	ICC = 0.916, 0.976	ICC = 0.999
Funakoshi, ¹¹ 2019	—	—	—	—	—	—	—
Matsumura, ²⁰ 2017	—	—	—	—	—	ICC > 0.9	ICC > 0.9
Schneider, ²⁷ 2017	—	—	—	—	—	80.3%, 90.1% ^c	71.8% ^c
MRI							
Gyftopoulos, ¹³ 2015	72.2	87.9	84.2	65	91	ICC = 0.73	ICC = 0.85
Kawakami, ¹⁶ 2019	—	—	—	—	—	ICC = 0.988	ICC = 0.988
Lau, ¹⁸ 2017	—	—	—	—	—	κ = 0.86	κ = 0.81
Shaha, ²⁸ 2016	—	—	—	—	—	ICC > 0.89	ICC > 0.89
MRI/MRA							
Metzger, ²¹ 2013	—	—	—	—	—	—	κ = 0.43
CT, MRI							
Locher, ¹⁹ 2016	—	—	—	—	—	—	—

^aDashes indicate that a study did not include data of that type. 2D, 2-dimensional; 3D, 3-dimensional; ABER, abduction and external rotation; ACC, accuracy; CT, computed tomography; HSL, Hill-Sachs lesion; IAAA, intact anterior articular angle; ICC, intraclass correlation coefficient; INTER, interobserver reliability; INTRA, intraobserver reliability; MRA, magnetic resonance arthrography; MRI, magnetic resonance imaging; NPV, negative predictive value; PPV, positive predictive value; SEN, sensitivity; SPE, specificity.

^bABER indicates CT of the shoulder in abduction and external rotation. IAAA indicates measurement of the intact anterior articular angle in addition to the glenoid lesion width on conventional 2D multiplane reformats.

^cPercentage of raters who agreed.

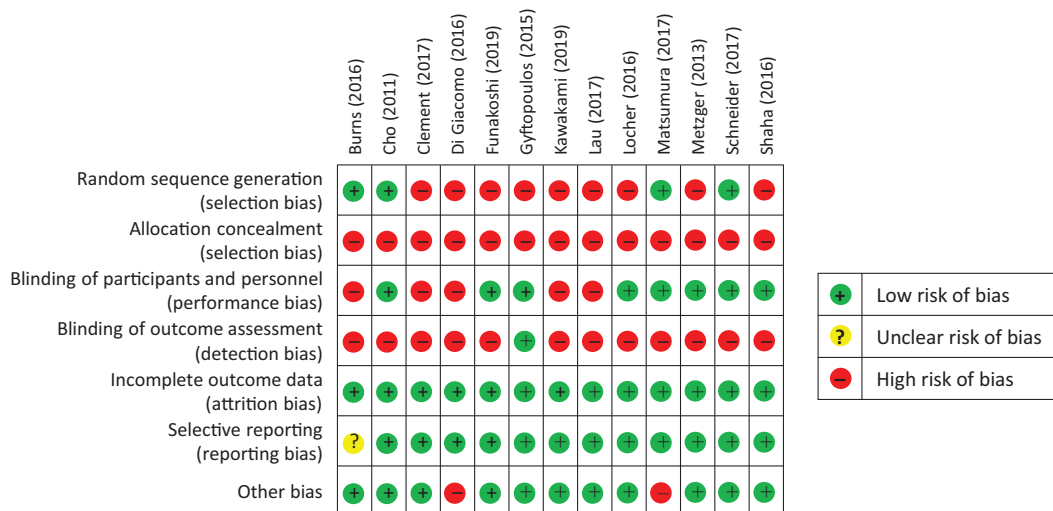


Figure 4. Quantitative bias found from papers in this systematic review.

directly compare these imaging modalities in the best way with regard to assessing GT method.

Six of the studies used 83% of glenoid width in their equation to calculate the GT,^{3,8,11,13,19,28} whereas 2 studies used 84% of the glenoid width.^{18,21} These numbers directly correspond to the percentage of the glenoid that

is equal to the width of the GT, which is the defined distance between the medial margin of the GT and the medial margin of the footprint of the rotator cuff.¹⁵ Yamamoto et al²⁹ found that the average distance in 9 cadavers from the medial margin of the contact area between the glenoid and the humeral head and the medial margin of the

footprint was 18.4 ± 2.5 mm, which was calculated to be $84\% \pm 14\%$ of the glenoid width with the arm at 60° of abduction. Yamamoto et al concluded that 84% of the glenoid width is equal to the GT in a cadaveric shoulder. However, Omori et al²³ found this value to be 83% of the glenoid at 90° of abduction in the shoulders of patients. Thus, 83% should be the most clinically accurate value used to measure GT.

2D-CT in the study of Burns et al³ had higher sensitivity, specificity, and accuracy for detecting on- and off-track HSLs than did MRI in the Gyftopoulos et al¹³ paper, but both authors concluded that their choice of imaging modality could be accurately used as a clinical tool to assess bone loss. However, Burns et al conducted a cadaveric study, while the study of Gyftopoulos et al was done clinically. Burns et al also confirmed their engaging versus nonengaging lesions by comparing their imaging measurements with measurements of separate arthroscopically created lesions. In their study, Gyftopoulos et al confirmed their engaging versus nonengaging lesions using arthroscopic findings. Thus, one is unable to formally compare these 2 imaging modalities using these 2 studies. Furthermore, Schneider et al²⁷ concluded that they had found “poor reliability” of the GT concept using 3D-CTs and did not recommend using this concept with 3D-CT in the treatment of instability. However, in their methods, they did specifically state how they calculated the width of the GT and determine if an HSL was engaging or nonengaging.

When confirming if an HSL is engaging or nonengaging, one can assess correctly in either of 2 ways: using a direct measurement arthroscopy of the GBL and HSL or using a dynamic evaluation with the arm in external rotation and 90° of abduction.¹⁵ However, as Parke et al²⁴ illustrated, to correctly evaluate if an HSL is engaging or nonengaging, one must perform a Bankart repair before restoring the capsuloligamentous complex. Otherwise, there will be high false-positive values in the results when indicating a lesion is engaging.²⁴ Although surgeons should perform a Bankart repair before conducting dynamic testing, they must be careful to not damage the repair when conducting the testing.^{9,15} In addition, doing a repair before assessing the GT could make performing a bone block procedure more difficult. Our results illustrated that Itoi¹⁵ and Di Giacomo et al⁹ used dynamic testing after performing Bankart repair while Cho et al,⁴ Gyftopoulos et al,¹³ Metzger et al,²¹ and Locher et al¹⁹ conducted testing before performing final fixation. This in turn could have resulted in the studies that used dynamic testing before their repair^{4,9,15} having skewed results.

The importance of correctly diagnosing off-track lesions was demonstrated by Locher et al¹⁹ and Shaha et al²⁸ who both found that an off-track lesion is much more likely to have recurrent instability (odds ratio of 8.3 for the need of revision surgery and a PPV of 75%). However, Clement et al⁵ found that there was no significant correlation between age and sex of a patient and the number of dislocations, while Lau et al¹⁸ and Matsumura et al²⁰ both found that larger numbers of instability events at a younger patient age did predict a higher off-track lesion incidence. They confirmed their results by retrospectively

comparing imaging results with patients’ surgical and clinical outcomes, such as stability and functional scores.

We suggest that given the current data, both CT and MRI are acceptable means to measure the GT. However, more data on accuracy of these techniques using the GT method is necessary to conclude if one is superior to the other.

This study was limited by the lack of comparable data over the accuracy and reliability of the GT concept in correctly predicting an on- or off-track HSL. Thus, this study was not able to pool a large number of shoulders together using similar measurements to really analyze the accuracy of one imaging modality over another. Only 2 studies actually assessed accuracy and used different gold standards to compare data.^{3,13} Studies also used different measurement techniques and variations in their equations to calculate the GT. In addition, this review included studies with variable evidence levels and bias levels, thereby adding to the limitations. Ultimately, this resulted in our inability to perform meta-analysis or directly compare these different imaging modalities, as this was the initial goal of our systematic review. However, our study showed that there is evidence to support the use of multiple imaging modalities to satisfactorily measure the GT and determine if an HSL in an instable shoulder is on- or off-track. Furthermore, to accurately compare MRI and CT imaging modalities regarding the GT method, researchers need to conduct randomized control studies that use an equation ($GT = [0.83 \times \text{glenoid width}] - GBL$) to determine whether an HSL is engaging or nonengaging and then confirm the results intraoperatively after Bankart repair.

CONCLUSION

Currently, there is evidence to support the use of different CT and MRI imaging modalities in assessing the GT method. However, the current literature illustrates some inconsistencies in how studies confirm whether HSLs are engaging or nonengaging, and no study has directly compared these different imaging modalities. In addition, few studies have compared radiographic measurements with a gold standard, and even fewer have looked at the GT concept as a predictor of outcomes. Thus, future studies are needed to further evaluate which imaging modality is the most accurate for assessing the GT.

REFERENCES

1. Bokor DJ, O’Sullivan MD, Hazan GJ. Variability of measurement of glenoid version on computed tomography scan. *J Shoulder Elbow Surg.* 1999;8(6):595-598.
2. Burkhart SS, De Beer JF. Traumatic glenohumeral bone defects and their relationship to failure of arthroscopic Bankart repairs: significance of the inverted-pear glenoid and the humeral engaging Hill-Sachs lesion. *Arthroscopy.* 2000;16(7):677-694.
3. Burns DM, Chahal J, Shahrokhi S, et al. Diagnosis of engaging bipolar bone defects in the shoulder using 2-dimensional computed tomography. *Am J Sports Med.* 2016;44(11):2771-2777.
4. Cho SH, Cho NS, Rhee YG. Preoperative analysis of the Hill-Sachs lesion in anterior shoulder instability: how to predict engagement of the lesion. *Am J Sports Med.* 2011;39(11):2389-2395.

5. Clement J, Menard J, Raison M, et al. Three-dimensional analysis of the locked position in patients with recurrent shoulder instability. *J Shoulder Elbow Surg.* 2017;26(3):536-543.
6. de Mello RAF, Ma Y-J, Ashir A, et al. Three-dimensional zero echo time magnetic resonance imaging versus 3-dimensional computed tomography for glenoid bone assessment. *Arthroscopy.* 2020;36(9):2391-2400.
7. Di Giacomo G, De Vita A, Costantini A, De Gasperis N, Scarso P. Management of humeral head deficiencies and glenoid track. *Curr Rev Musculoskelet Med.* 2014;7(1):6-11.
8. Di Giacomo G, Golijanin P, Sanchez G, Provencher MT. Radiographic analysis of the Hill-Sachs lesion in anteroinferior shoulder instability after first-time dislocations. *Arthroscopy.* 2016;32(8):1509-1514.
9. Di Giacomo G, Itoi E, Burkhart SS. Evolving concept of bipolar bone loss and the Hill-Sachs lesion: from “engaging/nonengaging” lesion to “on-track/off-track” lesion. *Arthroscopy.* 2014;30(1):90-98.
10. Fox JA, Sanchez A, Zajac TJ, Provencher MT. Understanding the Hill-Sachs lesion in its role in patients with recurrent anterior shoulder instability. *Curr Rev Musculoskelet Med.* 2017;10(4):469-479.
11. Funakoshi T, Hartzler RU, Stewien E, Burkhart SS. Hill-Sachs lesion classification by the glenoid track paradigm in shoulder instability: poor agreement between 3-dimensional computed tomographic and arthroscopic methods. *Arthroscopy.* 2019;35(6):1743-1749.
12. Galvin JW, Ernat JJ, Waterman BR, Stadecker MJ, Parada SA. The epidemiology and natural history of anterior shoulder instability. *Curr Rev Musculoskelet Med.* 2017;10(4):411-424.
13. Gyftopoulos S, Beltran LS, Bookman J, Rokito A. MRI evaluation of bipolar bone loss using the on-track off-track method: a feasibility study. *AJR Am J Roentgenol.* 2015;205(4):848-852.
14. Higgins JP, Altman DG, Gotzsche PC, et al. The Cochrane Collaboration’s tool for assessing risk of bias in randomised trials. *BMJ.* 2011;343:D5928.
15. Itoi E. “On-track” and “off-track” shoulder lesions. *EFORT Open Rev.* 2017;2(8):343-351.
16. Kawakami J, Yamamoto N, Etoh T, et al. In vivo glenoid track width can be better predicted with the use of shoulder horizontal extension angle. *Am J Sports Med.* 2019;47(4):922-927.
17. Kwon YW, Powell KA, Yum JK, Brems JJ, Iannotti JP. Use of 3-dimensional computed tomography for the analysis of the glenoid anatomy. *J Shoulder Elbow Surg.* 2005;14(1):85-90.
18. Lau BC, Conway D, Curran PF, Feeley BT, Pandya NK. Bipolar bone loss in patients with anterior shoulder dislocation: a comparison of adolescents versus adult patients. *Arthroscopy.* 2017;33(10):1755-1761.
19. Locher J, Wilken F, Beitzel K, et al. Hill-Sachs off-track lesions as risk factor for recurrence of instability after arthroscopic Bankart repair. *Arthroscopy.* 2016;32(10):1993-1999.
20. Matsumura N, Oki S, Kitashiro M, et al. Three-dimensional quantitative analysis of humeral head and glenoid bone defects with recurrent glenohumeral instability. *J Shoulder Elbow Surg.* 2017;26(9):1662-1669.
21. Metzger PD, Barlow B, Leonardelli D, et al. Clinical application of the “glenoid track” concept for defining humeral head engagement in anterior shoulder instability: a preliminary report. *Orthop J Sports Med.* 2013;1(2):2325967113496213.
22. Ohl X, Lagace PY, Billuart F, et al. Robustness and reproducibility of a glenoid-centered scapular coordinate system derived from low-dose stereoradiography analysis. *J Appl Biomech.* 2015;31(1):56-61.
23. Omori Y, Yamamoto N, Koishi H, et al. Measurement of the glenoid track in vivo as investigated by 3-dimensional motion analysis using open MRI. *Am J Sports Med.* 2014;42(6):1290-1295.
24. Parke CS, Yoo JH, Cho NS, Rhee YG. Arthroscopic remplissage for humeral defect in anterior shoulder instability: is it needed? Paper presented at: the 39th Annual Meeting of Japan Shoulder Society; October 5-6, 2012; Tokyo, Japan.
25. Provencher MT, Bhatia S, Ghodadra NS, et al. Recurrent shoulder instability: current concepts for evaluation and management of glenoid bone loss. *J Bone Joint Surg Am.* 2010;92(suppl 2):133-151.
26. Saliken DJ, Bornes TD, Bouliane MJ, Sheps DM, Beaupre LA. Imaging methods for quantifying glenoid and Hill-Sachs bone loss in traumatic instability of the shoulder: a scoping review. *BMC Musculoskelet Disord.* 2015;16:164.
27. Schneider AK, Hoy GA, Ek ET, et al. Interobserver and intraobserver variability of glenoid track measurements. *J Shoulder Elbow Surg.* 2017;26(4):573-579.
28. Shaha JS, Cook JB, Rowles DJ, et al. Clinical validation of the glenoid track concept in anterior glenohumeral instability. *J Bone Joint Surg Am.* 2016;98(22):1918-1923.
29. Yamamoto N, Itoi E, Abe H, et al. Contact between the glenoid and the humeral head in abduction, external rotation, and horizontal extension: a new concept of glenoid track. *J Shoulder Elbow Surg.* 2007;16(5):649-656.