



Contents lists available at ScienceDirect

Journal of Hand Surgery Global Online

journal homepage: www.JHSGO.org

Original Research

Nonsurgical Treatment for Acute Posttraumatic Distal Radioulnar Joint Instability: A Case Series



Andrew J. Bachinskas, MD,^{*} Elizabeth A. Helsper, MD,^{*} Harry A. Morris, MD,^{*,†}
Bernard F. Hearon, MD^{*,†}

^{*} Department of Orthopaedic Surgery, University of Kansas School of Medicine—Wichita, Wichita, KS

[†] Advanced Orthopaedic Associates, PA, Wichita, KS

ARTICLE INFO

Article history:

Received for publication July 22, 2019

Accepted in revised form October 6, 2019

Available online December 4, 2019

Key words:

Distal radioulnar joint instability

Nonsurgical treatment

Ulnar-sided wrist pain

Wrist sprain

Purpose: We investigated the clinical outcomes of patients with acute posttraumatic distal radioulnar joint (DRUJ) instability who were treated with our nonsurgical protocol.

Methods: The electronic database of our community-based orthopedic practice was queried to identify patients with posttraumatic wrist pain and DRUJ instability who presented for treatment less than 6 weeks after injury. Medical records review defined a cohort of 16 patients treated between November, 2000 and December, 2016 with immobilization of the wrist and elbow for 6 weeks and gradual return to full activity at 6 months after injury. Data from the medical records were compiled and analyzed to assess short-term outcomes. Eight patients with a minimum 2-year follow-up completed questionnaires and underwent a wrist-focused examination to assess long-term outcomes. We used Wilcoxon signed-ranks exact test and McNemar chi-square exact test to confirm the statistical significance of observed trends in key outcome measures.

Results: At a mean long-term follow-up of 6.7 years, there was statistically significant improvement in ulnar-sided wrist pain and all eight subjects examined demonstrated a negative dorsopalmar stress test indicating improved DRUJ stability. Analysis of the entire cohort showed that 11 of 16 patients (69%) were overall improved with respect to wrist pain and DRUJ stability at final follow-up evaluation. Ulnar-positive variance was a relative contraindication to nonsurgical treatment.

Conclusions: Prompt above-elbow immobilization of patients with acute posttraumatic DRUJ instability may result in a good clinical outcome without operative treatment.

Type of study/level of evidence: Therapeutic IV.

Copyright © 2019, THE AUTHORS. Published by Elsevier Inc. on behalf of The American Society for Surgery of the Hand. This is an open access article under the CC BY-NC-ND license (<http://creativecommons.org/licenses/by-nc-nd/4.0/>).

Wrist pain after a fall onto an outstretched upper extremity is a common report of patients presenting to emergency departments and urgent care centers.^{1,2} For the typical closed injury, initial wrist examination may be difficult or inconclusive and, in most cases, wrist radiographs are normal with no fracture identified.³ Many of these patients are given the diagnosis of wrist sprain and are treated symptomatically with a removable short-arm orthosis or

compressive wrap. Follow-up care is highly variable and may be delayed for weeks after the injury.

Despite having negative injury radiographs, these patients may have sustained soft tissue injuries of the wrist.⁴ For instance, those with posttraumatic ulnar-sided wrist pain may have triangular fibrocartilage complex (TFCC) disruption resulting in distal radioulnar joint (DRUJ) instability.⁵ This diagnosis may be made on clinical grounds without relying on advanced imaging.^{6,7} Our approach to patients with clinical evidence of DRUJ instability seen soon after the causative wrist trauma has been to immobilize the affected wrist and elbow for 6 weeks and restrict heavy lifting and sports activity for 6 months after the injury.

The purpose of this study was to assess the outcomes of patients with acute posttraumatic DRUJ instability treated with our nonsurgical protocol. We assessed overall patient satisfaction with

Declaration of interests: No benefits in any form have been received or will be received by the authors related directly or indirectly to the subject of this article.

Corresponding author: Bernard F. Hearon, MD, Department of Orthopaedic Surgery, University of Kansas School of Medicine—Wichita, 929 Saint Francis, #4076, Wichita, KS 67214.

E-mail address: bhearon@cox.net (B.F. Hearon).

<https://doi.org/10.1016/j.jhsg.2019.10.002>

2589-5141/Copyright © 2019, THE AUTHORS. Published by Elsevier Inc. on behalf of The American Society for Surgery of the Hand. This is an open access article under the CC BY-NC-ND license (<http://creativecommons.org/licenses/by-nc-nd/4.0/>).

the clinical outcome and the necessity for operative treatment. We hypothesized that patients immobilized for DRUJ instability in the early postinjury stage would have improvement in ulnar-sided wrist pain and DRUJ stability at follow-up evaluation.

Materials and Methods

We searched the electronic database at Advanced Orthopaedic Associates to identify all patients with International Classification of Diseases (ICD) codes for wrist pain and instability from November, 2000 to December, 2016. In the ICD, Ninth Revision, these codes were 719.43 and 718.33, respectively, whereas in the ICD, 10th Revision, these codes were M25.53x and M24.43x, respectively. Inclusion in the study cohort required a known causative wrist injury, a positive dorsopalmar stress test⁸ that reproduced the ulnar-sided wrist pain, and a 6-week period of wrist and elbow immobilization initiated within 6 weeks of the injury date. Exclusion criteria were concomitant wrist fracture, preexisting wrist arthropathy, or previous wrist surgery.

Our conservative treatment protocol consisted of immobilizing the patient in a single sugar-tong orthosis composed of 4-in plaster as soon as possible after the wrist injury. The patient's elbow was flexed 90°, the forearm was placed in neutral rotation, and the wrist was mildly ulnarly deviated. Typically, the orthosis was changed at 2-week intervals during the 6 weeks of immobilization. The patient was then transitioned to a removable short-arm orthosis for 2–4 weeks with instructions to minimize heavy lifting and sports activity until 6 months after the injury, when unrestricted activity was permitted.

Written or electronic medical records of all patients in the study cohort were reviewed with a focus on changes in wrist pain and DRUJ stability during the short-term episode of care, from 6 weeks to 6 months after the injury. Long-term outcomes, determined at a minimum 2-year follow-up, were assessed by enrolling patient volunteers in a research protocol approved by the University of Kansas School of Medicine–Wichita Institutional Review Board. Informed consent was obtained from all subjects in the study.

We administered questionnaires to subjects by telephone interview or in the office to assess long-term relief of wrist pain and instability symptoms and satisfaction with the nonsurgical treatment protocol. The *Quick–Disabilities of the Arm, Shoulder, and Hand* survey,⁹ an 11-item validated outcome instrument, was scored on a 0 to 100 scale, in which higher scores indicated greater subject impairment. Pre- and posttreatment wrist pain severity was scored on a 10-point visual analog scale, in which 0 indicated no pain and 10 implied severe pain. Objective data, including the presence or absence of DRUJ stability based on the dorsopalmar stress test,⁸ wrist range of motion, and grip strength, were derived from subjects who returned for long-term follow-up examination. Wrist motion was measured with a handheld goniometer and grip strength was measured with a Jamar dynamometer (Model 0030J4, Therapeutic Equipment Corporation, Clifton, NJ). Collected data on pain level or severity, employment status, wrist range of motion, and grip strength were used to calculate a modified Mayo wrist score,¹⁰ which is a outcome measure scaled 0 to 100. Subjects scoring in the 91 to 100 range were rated as excellent outcomes, 80 to 90 as good, 64 to 79 as fair, and 0 to 64 as poor.

Data were collected and managed in an electronic database^{11,12} at the University of Kansas School of Medicine. Standard descriptive statistics including measures of central tendency (mean) and variance (SD and range), occurrence frequencies and proportions were calculated and reported. Owing to the small number of matched-pair data available for analysis, Wilcoxon signed-ranks exact test and McNemar chi-square exact test were used to determine the significance of posttreatment clinical trends in wrist pain

and DRUJ stability, respectively. We chose $\alpha = 0.05$ as the level of statistical significance with 2-tailed test results reported.

Results

During the 16-year study period, 160 patients (161 limbs) sought treatment from the senior authors for wrist pain owing to DRUJ instability, most presenting 6 weeks or more after the injury. Of the 142 extremities with subacute or chronic DRUJ instability, 36 (25%) had sustained a prior fracture that contributed to the instability and 70 (49%) underwent operative treatment for DRUJ stabilization (Table 1).

Nineteen of the 160 patients (12%) presented to us acutely, less than 6 weeks after the ligamentous wrist injury. Eighteen had screening radiographs of the injured wrist; the remaining patient had wrist magnetic resonance imaging (MRI). All of these studies were negative for wrist fracture, dorsal subluxation of the ulna, or other carpal pathology. One patient had a minimally displaced radial neck fracture. All patients were offered 6 weeks of immobilization as primary treatment for DRUJ instability. Of the 19 patients seen during the acute postinjury phase, 16 complied with the treatment protocol and comprise the cohort under study (Fig. 1).

Patient demographics defining the study cohort (Table 2) included a mean age of 37 years (range, 12–77 years) and mean delay time between injury and treatment of 15 days (range, 2–39 days). Most patients (63%) were women and most were right-handed. The most common mechanism of injury was a fall onto an outstretched upper extremity, which occurred in 75% of the group. The 4 non-fall injuries involved untoward wrist or forearm rotation in the mechanism of injury. A minority of injuries ($n = 4$) involved workers' compensation claims.

All 16 patients in the study cohort had short-term follow-up at an average of 3.3 ± 1.5 months (range, 1.4–6.1 months). Two patients were only somewhat clinically improved; a third patient with an ongoing workers' compensation claim had persistent wrist pain and instability sufficient to require a DRUJ stabilization procedure for failed immobilization (Table 3). The latter patient and one of those who was somewhat improved were the only cohort members found to have ulnar-positive variance 2 mm or greater. Two additional patients completed the 6-week immobilization protocol but did not return for further follow-up.

At final clinical evaluation, 11 of 16 patients in the study cohort (69%) had complete or near-complete resolution of wrist pain at rest and under loading conditions, as well as firm end points on dorsopalmar stress test and no difference in DRUJ laxity of the injured wrist compared with the uninjured side. This group included all 8 patients available for long-term follow-up at an average of 6.7 ± 3.0 years (range, 3.3–11.8 years) after the injury.

Analysis of the long-term outcome data on the 8 patients revealed marked improvement in mean ulnar-sided wrist pain on the visual analog scale from pretreatment (7.7 ± 1.0) to posttreatment (0.3 ± 0.5). This difference was statistically significant by Wilcoxon signed-ranks exact test ($P = .03$). All subjects examined at the long-term encounter had negative dorsopalmar stress test indicating statistically significant improvement in DRUJ stability by McNemar chi-square exact test ($P = .008$). Posttreatment *Quick–Disabilities of the Arm, Shoulder, and Hand* scores were favorable (range, 0–10). Modified Mayo wrist scores were stratified as 3 excellent, 4 good, 1 fair, and 0 poor. All subjects contacted at long-term follow-up were satisfied with the nonsurgical treatment outcome.

Table 1
Injury Characterization and Approach to Treatment Based on Chronicity of DRUJ Instability*

Injury Type or Treatment Method	Acute (< 6 wk) (n = 19)	Subacute or Chronic (> 6 wk) (n = 142)
Soft tissue injury only	18 (95%)	106 (75%)
Fracture resulting in instability	1 (5%)	36 (25%)
Distal radius and/or ulna	0	26
Radial and/or ulnar shaft	0	6
Radial head and/or neck	1	2
Unspecified	0	2
Nonsurgical treatment	19	72 (51%)
Six-wk immobilization protocol	16	3
Declined treatment, noncompliant, or lost to follow-up	3	7
No treatment required, minimal symptoms		33
Declined surgery		21
Removable orthosis, injection, or hand therapy		8
Operative treatment	1 of 16 (6%) [†]	70 (49%)

* Parameter values are presented as patient limb counts (percentage of total).

[†] One of 16 patients treated nonsurgically had persistent wrist pain and required later operative stabilization.

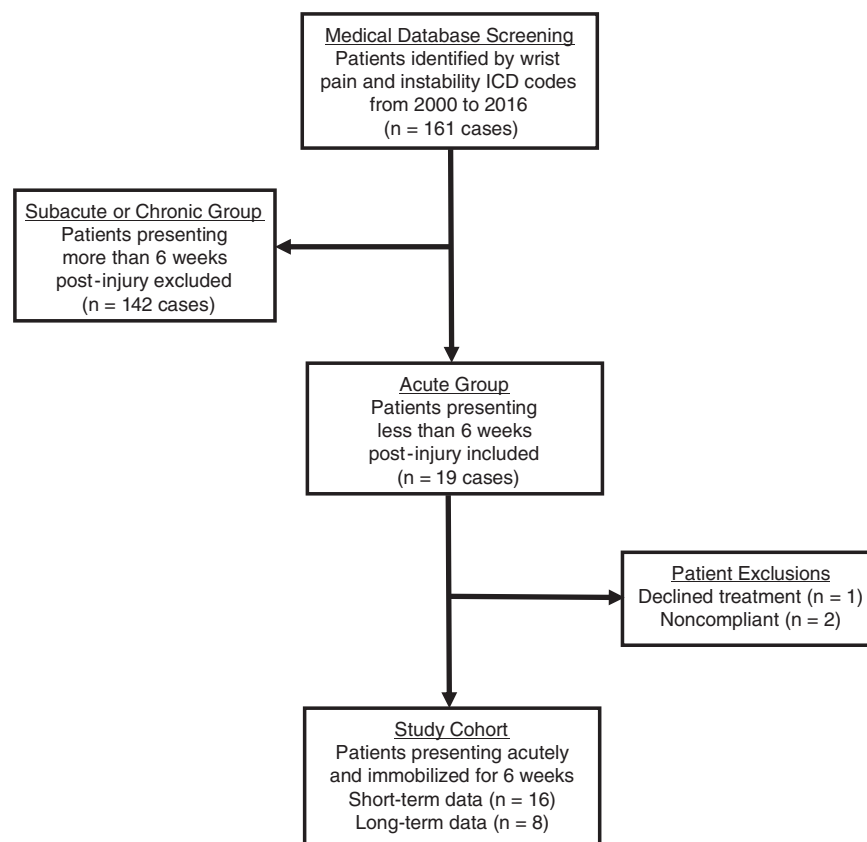


Figure 1. Schematic flowchart defining study cohorts. ICD, International Classification of Diseases.

Discussion

Based on the favorable clinical outcomes presented, continuous immobilization of the wrist and elbow for 6 weeks should be considered for patients with acute posttraumatic DRUJ instability attributed to TFCC disruption without associated wrist fracture. We are unaware of other outcome studies of nonsurgical treatment for DRUJ instability to which our results may be compared. Ulnar-positive variance (≥ 2 mm) in 2 of the 3 treatment failures suggests that nonsurgical treatment is relatively contraindicated in those who are ulnar-positive.

We believe that early immobilization within 6 weeks of an acute wrist injury permits healing of the deep fibers of the dorsal and

palmar radioulnar ligaments to the well-vascularized ulnar fovea, thereby restoring DRUJ stability and improving ulnar-sided wrist pain. Kleinman⁷ referred to these deep ligamentous fibers of the TFCC (Fig. 2) as the primary stabilizer of the DRUJ. Immobilization also allows healing of the DRUJ secondary stabilizers, including the superficial dorsal and palmar radioulnar ligaments^{7,13,14} and the DRUJ capsule.¹⁵

Patients not adequately and opportunistically immobilized may continue to stretch the injured ligaments with potential for progression to chronic DRUJ instability. By way of illustration, one patient in the study sustained TFCC disruption bilaterally when she fell forward onto both outstretched upper extremities. Presenting with bilateral wrist pain and DRUJ instability, she was treated with

Table 2
Patient Demographics*

Characteristic	Acute Injuries (< 6 wk) (n = 16)
Age at presentation, y	37.3 ± 19.9 (12–77)
Time from injury to treatment, d	15.3 ± 11.3 (2–39)
Gender (female)	10 (62.5%)
Hand dominance (right)	15 (94%)
Symptomatic side (right)	6 (37.5%)
Workers' compensation claim	4 (25%)
Mechanism of injury	
Fall on outstretched hand	12 (75%)
Lifting injury	2 (12.5%)
Blunt trauma or twisting injury	2 (12.5%)

* Values are presented as patient counts (percentage of total) or mean ± SD (range).

continuous above-elbow immobilization for 6 weeks on the more symptomatic and relatively more unstable left side and, by necessity, with intermittent immobilization using a removable short-arm orthosis on the right (although she met our indications for continuous immobilization on both sides). Her favorable outcome on the left side is reported in this study. However, on the right side, she had persistent wrist pain owing to DRUJ instability, for which she ultimately required operative stabilization. The importance of timely nonsurgical treatment for acute DRUJ instability is also supported by the finding that the patients in the current study were more likely to require operative treatment when they presented more than 6 weeks after the injury (49%), compared with those presenting less than 6 weeks afterward (6%), as shown in Table 1.

During this 16-year study, just 19 of 160 patients (12%) were referred to us early enough to permit effective nonsurgical treatment, which suggests that DRUJ instability may not be well-appreciated by some providers evaluating wrist trauma patients. Posttraumatic ulnar-sided wrist pain after a fall onto an outstretched hand with the wrist dorsiflexed or after an injury involving forced wrist or forearm rotation should raise the clinician's index of suspicion for DRUJ instability, because these are the 2 most common injury mechanisms for TFCC tear.⁵ cursory inspection of the wrist may be unrevealing or may show nonspecific swelling or bruising, but when radiographs of the wrist are negative for fracture, a more comprehensive timely examination of the wrist⁸ is mandatory to establish the clinical diagnosis and allow for the correct treatment or referral plan.

A prominent distal ulna, volar sag of the ulnar carpus, and positive piano key test¹⁶ suggest dorsal instability of the distal ulna with respect to the radius and should lead the examiner to perform additional provocative tests (Table 4). During the ulnocarpal stress test,¹⁷ axial and rotational loads are simultaneously applied across the ulnocarpal joint. If this maneuver elicits wrist pain, popping, or both, a TFCC tear may be present, but other ulnar wrist pathology is not necessarily excluded. Additional physical exam provocations, including the lunotriquetral (LT) ballottement test¹⁸ and the LT shear test,⁸ are specific for LT instability but may also be positive in patients with TFCC tear and DRUJ instability.

Table 3
Outcomes Based on Improvement in Wrist Pain and DRUJ Stability*

Clinical Outcome	Long-Term Follow-Up (n = 8)	Short- or Long-Term Follow-Up (n = 16)
Wrist pain and instability improved	8 (100%)	11 (69%)
Somewhat clinically improved	0	2
No clinical improvement	0	1
Lost to follow-up after 6 wk		2

* Values are presented as patient counts (percentage of total).

More highly sensitive and specific provocative maneuvers for TFCC disruption from the foveal attachment should be performed whenever DRUJ instability is suspected. The ulnar fovea sign¹⁹ is positive when pain is reproduced on foveal palpation between the ulnar styloid and flexor carpi ulnaris. The press test⁶ and modified press test²⁰ are positive when pain is reproduced with axial forearm loading, as demonstrated by pushing up from a seated position. Observable subluxation of the distal ulna may also occur as the patient pushes off from a chair side rail or table with the symptomatic dorsiflexed wrist.

In this study, the clinical reference standard used to diagnose DRUJ instability was the dorsopalmar stress test.^{7,8} Current understanding of TFCC functional anatomy is that the deep fibers of the palmar and dorsal radioulnar ligaments insert at the ulnar fovea and act as primary stabilizers of the DRUJ.^{7,14,21} The deep palmar radioulnar ligament is taut in pronation and functions as a check-rein against dorsal displacement of the ulna with respect to the radius. Conversely, the deep dorsal radioulnar ligament is taut in supination and serves to limit palmar translation of the distal ulna. The integrity of these key DRUJ stabilizers may be reliably assessed using the dorsopalmar stress test, which is analogous to the anteroposterior drawer (load and shift) test for glenohumeral joint instability.²²

Proper execution of the dorsopalmar stress test requires the clinician to examine the wrist in neutral rotation, full pronation, and full supination, and to compare the ulnar translation found on the injured side with laxity appreciated in the uninjured wrist. With the patient's forearm in full pronation, the examiner applies dorsal-directed stress to the distal ulna while stabilizing the radiocarpal unit (Fig. 3A). The provocation indicates incompetence of the deep palmar radioulnar ligament when the examiner perceives increased laxity compared with examination of the uninjured side and the maneuver reproduces the patient's wrist pain (Fig. 3B). Similarly, in supination with application of palmar-directed stress (Fig. 3C), competence of the deep dorsal radioulnar ligament may be evaluated (Fig. 3D). We prefer to stabilize the radiocarpal articulation manually before applying stress to the distal ulna, rather than applying concurrent and opposite stress to the radius as described by Kleinman,⁷ because in our experience a more reliable determination of ulnar translation is possible when the initial position of the radius is stable with respect to the ulna. The provocation is negative when there are firm end points without side-to-side laxity difference appreciated on dorsopalmar stress test at the extremes of pronosupination and wrist pain is not reproduced by the maneuver.

Thin-section, high-resolution wrist MRI may have been used to confirm TFCC tears²³ in the current cohort. However, the results of this advanced imaging would not have changed our initial nonsurgical treatment plan. We agree with Kleinman^{7,8} that assessment of DRUJ instability should be made on clinical grounds without relying on MRI evaluation. Our experience has been that wrist MRI is not necessary to establish a diagnosis and often may be regarded as a waste of health care resources, as others have observed.²⁴ We prefer to use wrist MRI as a preoperative planning tool for those who have failed nonsurgical treatment.

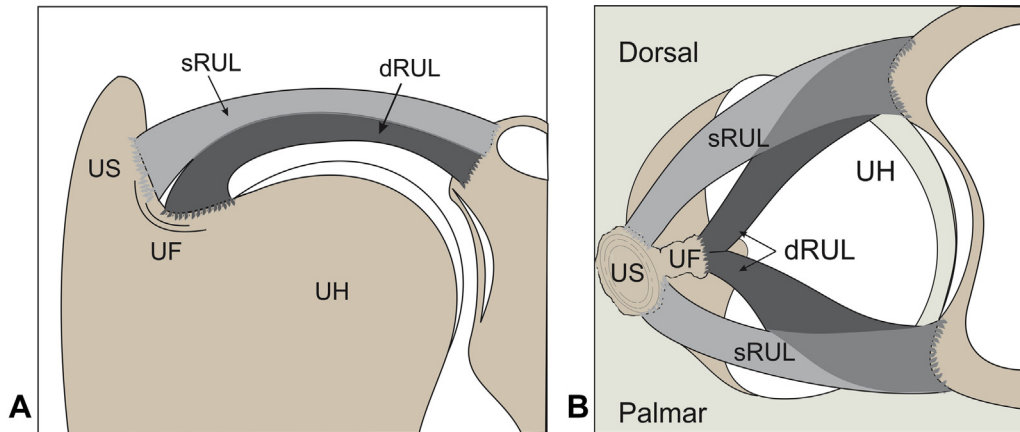


Figure 2. Diagram of the left wrist with DRUJ key stabilizers. Deep dorsal and palmar radioulnar ligaments attach to the ulnar fovea; superficial dorsal and palmar radioulnar ligaments attach to the ulnar styloid. **A** Oblique, near coronal plane view. **B** Axial view. dRUL, deep radioulnar ligament; sRUL, superficial radioulnar ligament; UF, ulnar fovea; UH, ulnar head; US, ulnar styloid.

Table 4
Provocative Tests to Evaluate Ulnar-Sided Wrist Pain and DRUJ Instability*

Provocative Maneuver	Description	Implication
Piano key test ¹⁶	With forearm pronated, dorsal-to-palmar ballottement of prominent distal ulna in sagittal plane	Upon release of palmar-directed stress, ulna returns to resting position, indicating dorsal instability
Ulnocarpal stress test ¹⁷	With wrist ulnarly deviated, wrist is passively pronosupinated while applying axial load to forearm	Reproduction of wrist pain suggests TFCC tear, ulnocarpal abutment, or other ulnar wrist pathology
Ulnar fovea sign ¹⁹	Using thumb tip, deep palpation of ulnar fovea between ulnar styloid and flexor carpi ulnaris	Exquisite tenderness indicates disruption of distal radioulnar ligaments and/or ulnotriquetral ligament
Press test ⁶ or modified press test ²⁰	Seated patient pushes up from chair, producing axial ulnar load on injured wrist	Replication of focal ulnar wrist pain and subluxation indicates TFCC tear with high sensitivity
Dorsopalmar stress test ⁷	Examiner stabilizes radiocarpal unit and then:	Reproduction of pain and perception of laxity indicates:
With forearm pronated	Palmar-to-dorsal stress is applied to distal ulna	Disruption of deep palmar radioulnar ligament
With forearm supinated	Dorsal-to-palmar stress is applied to distal ulna	Disruption of deep dorsal radioulnar ligament

* The radiocarpal unit is mobile in pronosupination about the fixed axis of the ulna. However, by convention, instability of the DRUJ is described in terms of dorsal or palmar displacement or subluxation of the distal ulna with respect to the radius. The dorsopalmar stress test is considered positive when the examiner perceives greater DRUJ laxity compared with the contralateral uninjured wrist and the maneuver reproduces the patient's wrist pain.

Immobilization of the unstable DRUJ in a nonremovable, single sugar tong orthosis proved to be a practical and effective method of treatment for patients in this study. Other acceptable methods of immobilization include long-arm orthosis, double sugar tong orthosis, Muenster cast, or long-arm cast, but these would be more costly and labor-intensive options. Although there were no complications of immobilization in our study, one patient who perceived motion at the DRUJ in the single sugar tong orthosis required immobilization in a long-arm posterior orthosis to achieve DRUJ stability. Because immobilization of the DRUJ requires control not only of wrist dorsiflexion and palmar flexion but also of forearm pronosupination, below-elbow orthoses or casts are not recommended for acute posttraumatic DRUJ instability.

Limitations of our report include the small number of patients available for study despite the relatively long collection period. Indeed, we hope that our results will prompt earlier referral of similar patients in the future. The study was also limited by the lack of a control group and the absence of advanced imaging or DRUJ arthroscopy to confirm the diagnosis, which was based solely on clinical grounds. As in other retrospective case series, our database was incomplete, lacking pertinent clinical parameters for some patients and long-term outcome data for those whom we were unable to contact. The possibility remains that some of these patients may have obtained further treatment elsewhere. Our results were also subject to patient recall bias and to examiner bias, which

may have influenced the manual dorsopalmar stress test or other physical findings. Notwithstanding these shortcomings, we believe that the efficacy of immobilization for acute posttraumatic DRUJ instability is supported by our data.

We believe that all patients with acute posttraumatic ulnar-sided wrist pain after a fall onto an outstretched hand or untoward wrist rotation and negative injury radiographs should be evaluated promptly for clinical signs of DRUJ instability. Those found to have a positive dorsopalmar stress test within 6 weeks of the injury may be treated with above-elbow immobilization and activity modification with the expectation of a good clinical outcome. However, ulnar-positive variance of 2 mm or greater is a relative contraindication to our nonsurgical treatment protocol.

Acknowledgments

Partial funding for use of Research Electronic Data Capture was by Clinical and Translational Science Award UL1TR002366 from the National Center for Advancing Translational Sciences at the National Institutes of Health. We gratefully acknowledge Rosalee E. Zackula, MA, research statistician at the University of Kansas School of Medicine in Wichita, for her assistance with the electronic database and statistical analysis for this study.

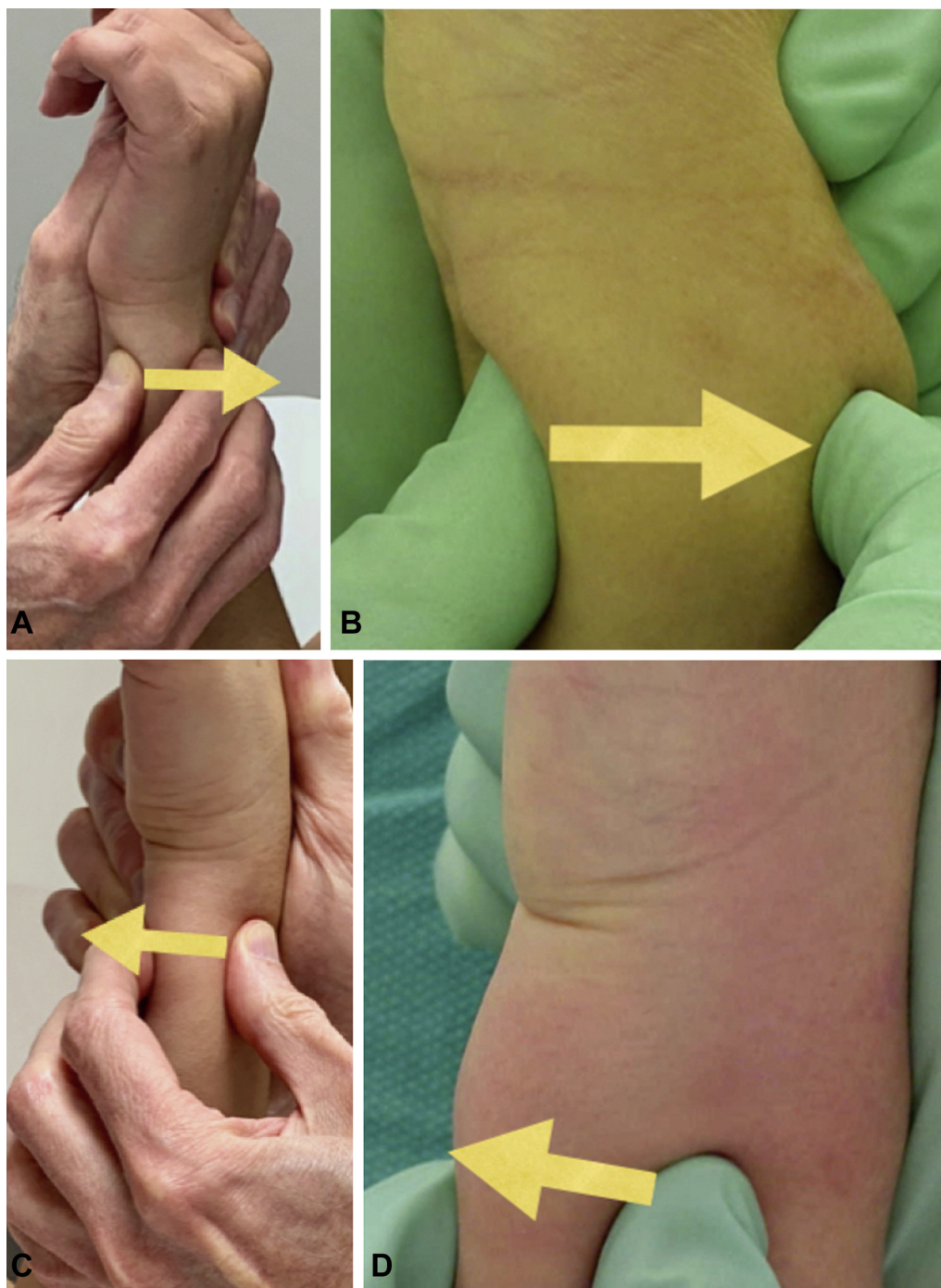


Figure 3. Dorsopalmar stress test for DRUJ instability. Left wrist is shown in all photos. Arrows indicate direction of stress application. **A** Normal wrist showing application of dorsal-directed stress to the distal ulna with the forearm fully pronated to assess integrity of deep palmar radioulnar ligament. **B** Unstable wrist demonstrating marked translation of distal ulna with dorsal-directed stress indicating incompetent deep palmar radioulnar ligament. **C** Normal wrist showing application of palmar-directed stress to the distal ulna with the forearm fully supinated to assess integrity of deep dorsal radioulnar ligament. **D** Unstable wrist demonstrating marked translation of distal ulna with palmar-directed stress indicating incompetent deep dorsal radioulnar ligament.

References

1. De Putter CE, Selles RW, Polinder S, Panneman MJM, Hovius SER, van Beeck EF. Economic impact of hand and wrist injuries: health-care costs and productivity costs in a population-based study. *J Bone Joint Surg Am.* 2012;94(9):e56.
2. Wenzinger E, Rivera-Barrios A, Gonzalez G, Herrera F. Trends in upper extremity injuries presenting to US emergency departments. *Hand (NY).* 2019;14(3):408–412.
3. Walenkamp MMJ, Bentohami A, Slaar A, et al. The Amsterdam wrist rules: the multicenter prospective derivation and external validation of a clinical decision rule for the use of radiography in acute wrist trauma. *BMC Musculoskelet Disord.* 2015;16:389.
4. Bergh TH, Lindau T, Bernardshaw SV, et al. A new definition of wrist sprain necessary after findings in a prospective MRI study. *Injury.* 2012;43(10):1732–1742.
5. Moritomo H, Masatomi T, Murase T, Miyake JI, Okada K, Yoshikawa H. Open repair of foveal avulsion of the triangular fibrocartilage complex and

- comparison by types of injury mechanism. *J Hand Surg Am.* 2010;35(12):1955–1963.
6. Lester B, Halbrecht J, Levy IM, Gaudinez R. “Press test” for office diagnosis of triangular fibrocartilage complex tears of the wrist. *Ann Plast Surg.* 1995;35(1):41–45.
 7. Kleinman WB. Stability of the distal radioulna joint: biomechanics, pathophysiology, physical diagnosis, and restoration of function: what we have learned in 25 years. *J Hand Surg Am.* 2007;32(7):1086–1106.
 8. Kleinman WB. Physical examination of the wrist: useful provocative maneuvers. *J Hand Surg Am.* 2015;40(7):1486–1500.
 9. Gummesson C, Ward MM, Atroshi I. The shortened disabilities of the arm, shoulder and hand questionnaire (QuickDASH): validity and reliability based on responses within the full-length DASH. *BMC Musculoskelet Disord.* 2006;7:44.
 10. Cooney WP, Bussey R, Dobyns JH, Linscheid RL. Difficult wrist fractures: perilunate fracture-dislocations of the wrist. *Clin Orthop Relat Res.* 1987;214:136–147.
 11. Harris PA, Taylor R, Thielke R, Payne J, Gonzalez N, Conde JG. Research electronic data capture (REDCap)—a metadata-driven methodology and workflow process for providing translational research informatics support. *J Biomed Inform.* 2009;42(2):377–381.
 12. Harris PA, Taylor R, Minor BL, et al. The REDCap consortium: building an international community of software platform partners. *J Biomed Inform.* 2019;95:103208.
 13. Haugstvedt JR, Berger RA, Nakamura T, Neale P, Berglund L, An KN. Relative contributions of the ulnar attachments of the triangular fibrocartilage complex to the dynamic stability of the distal radioulnar joint. *J Hand Surg Am.* 2006;31(3):445–451.
 14. Stuart PR, Berger RA, Linscheid RL, An KN. The dorsopalmar stability of the distal radioulnar joint. *J Hand Surg Am.* 2000;25(4):689–699.
 15. Watanabe H, Berger RA, An KN, Berglund LJ, Zobitz ME. Stability of the distal radioulnar joint contributed by the joint capsule. *J Hand Surg Am.* 2004;29(6):1114–1120.
 16. Glowacki KA, Shin LA. Stabilization of the unstable distal ulna: the Linscheid-Hui procedure. *Tech Hand Up Extrem Surg.* 1999;3(4):229–236.
 17. Nakamura R, Horii E, Imaeda T, Nakao E, Kato H, Watanabe K. The ulnocarpal stress test in the diagnosis of ulnar-sided wrist pain. *J Hand Surg Br.* 1997;22(6):719–723.
 18. Reagan DS, Linscheid RL, Dobyns JH. Lunotriquetral sprains. *J Hand Surg Am.* 1984;9(4):502–514.
 19. Tay SC, Tomita K, Berger RA. The “ulnar fovea sign” for defining ulnar wrist pain: an analysis of sensitivity and specificity. *J Hand Surg Am.* 2007;32(4):438–444.
 20. Adams BD. Anatomic reconstruction of the distal radioulnar ligaments for DRUJ instability. *Tech Hand Up Extrem Surg.* 2000;4(3):154–160.
 21. Omokawa S, Iida A, Kawamura K, et al. A biomechanical perspective on distal radioulnar joint instability. *J Wrist Surg.* 2017;6(2):88–96.
 22. Silliman JF, Hawkins RJ. Classification and physical diagnosis of instability of the shoulder. *Clin Orthop Relat Res.* 1993;291:7–19.
 23. Potter HG, Asnis-Ernberg L, Weiland AJ, Hotchkiss RN, Peterson MGE, McCormack RR. The utility of high-resolution magnetic resonance imaging in the evaluation of the triangular fibrocartilage complex of the wrist. *J Bone Joint Surg Am.* 1997;79(11):1675–1684.
 24. Babbel D, Rayan G. Magnetic resonance imaging in evaluating workers' compensation patients. *J Hand Surg Am.* 2012;37(4):811–815.