

Journal of Hand Surgery

THE PASSIVE STRAIN DISTRIBUTION IN THE INTEROSSEOUS LIGAMENT OF THE FOREARM: IMPLICATIONS FOR INJURY RECONSTRUCTION

Mary T. Gabriel, M.S., H. James Pfaeffle, M.D., Ph.D., Kathryne J. Stabile, M.S.,

Matthew M. Tomaino, M.D. *, Kenneth J. Fischer, Ph.D. +

Musculoskeletal Research Center, Department of Orthopaedic Surgery,
University of Pittsburgh, Pittsburgh Pennsylvania
*University of Rochester, Rochester, New York
+University of Kansas, Lawrence, Kansas

Running Title: Passive Strain in the Interosseous Ligament

Key Words: Forearm, Interosseous Ligament, Reconstruction, Strain, Strain Distribution

Correspondence:

Kenneth J. Fischer, Ph.D.
Mechanical Engineering
University of Kansas
1530 W. 15th Street, 3013 Learned Hall
Lawrence, KS 66045

Tel: 785-864-2994
FAX: 785-864-5254
Sec: 785-864-3181
E-mail: fischer@ku.edu

Abstract

PURPOSE: For severe forearm injuries, such as an Essex-Lopresti lesion, functional reconstruction necessitates repair of the interosseous ligament (IOL) to restore normal load sharing between the radius and ulna. Improperly locating or tensioning such a reconstruction can lead to abnormal load sharing and/or restriction of forearm rotation. The normal IOL strains should indicate the proper location of reconstruction grafts and the proper forearm rotation for tensioning the grafts. The objective of this study was to quantify the passive strain distribution of the IOL of the forearm with passive rotation of the forearm throughout the range of motion.

METHODS: The 3-D motions of the radius with respect to the ulna were measured throughout forearm rotation in ten cadaveric forearms using an instrumented spatial linkage. From the bone motions and ligament insertion site geometry from dissection and CT scanning, insertion site motions were determined and used to calculate changes in ligament fiber lengths.

RESULTS: The measured strain distribution in the IOL was non-uniform and varied with forearm rotation. The overall magnitude of IOL strain was found to be greatest in supination and smallest in pronation. Also, in supination, the strains varied across fibers, with strains being greatest in the distal fibers and lowest in the proximal fibers. Strains in neutral rotation were uniform across fibers. While fibers were generally slack in pronation, proximal fibers were less slack than distal fibers.

CONCLUSIONS: The results of this study indicate that fiber strains in the IOL vary from proximal to distal and depend on forearm rotation. Our data suggests that to prevent restriction of forearm rotation, all grafts should be tensioned in supination, where measured strains were generally highest. Our data also suggests that a two bundle IOL reconstruction may be necessary for proper load transfer between the radius and ulna in both supination and pronation.

Introduction

The interosseous membrane of the forearm plays an important role in forearm stability and its main structural component is the strong ligamentous band of tissue in the central third of the forearm, described as the interosseous ligament (IOL) ¹⁻³. The fibers of the IOL run obliquely from a more proximal insertion on the radius to a more distal insertion on the ulna.

The Essex-Lopresti fracture-dislocation is characterized by fracture of the radial head, proximal migration of the radius with respect to the ulna, dislocation of the distal radioulnar joint, and tearing of the IOL ^{4,5}. This injury is difficult to treat and may result in limited forearm rotation and pain at the wrist ⁵⁻⁷. Treatment of an Essex-Lopresti lesion usually addresses only the radial head fracture. Even if the distal radioulnar dislocation is adequately addressed, such treatment ignores the interosseous ligament and leads to poor (at best inconsistent) functional results ^{8,9}.

Reconstruction of the interosseous ligament has been suggested to prevent chronic forearm instability resulting from the Essex-Lopresti injury ¹⁰. A better understanding of the biomechanics of the intact IOL is necessary to develop a successful IOL reconstruction. The IOL has been shown to resist proximal migration of the radius following radial head excision ¹¹ as well as transfer load from the radius to the ulna when a compressive load is applied to the hand ¹²⁻¹⁵. Strain in the IOL has been studied with load applied to the hand in fixed positions, and was found to be greater in neutral rotation than in supination or pronation ^{8,18}. Furthermore, in supination, the strains were higher in the distal fibers than in the proximal fibers, whereas in neutral rotation strain was relatively uniform ^{3,16}.

Reconstructive grafts are surgically implanted in the forearm when there is no loading present. Therefore, a passive (unloaded) strain distribution is relevant and useful for graft

tensioning. If a reconstructive graft is tensioned with the forearm improperly rotated, the subsequent active rotation of the forearm may be limited. Passive strain is also relevant for active rotation of the forearm when there is no grip and the forearm muscles are relaxed. Data from only the three standard configurations of forearm rotation (supination, neutral rotation, and pronation) is insufficient to determine the position of maximum strain, since maximum strain could occur between these positions. Thus, the objective of this study was to quantify the passive strain distribution in the fibers of the IOL throughout the range of passive rotation of the forearm, without an externally applied load.

Materials and Methods

Ten fresh-frozen human cadaveric forearms (ages 36-75) were stored at -20°F and thawed 24 hours prior to dissection¹⁷. All the soft tissues in the mid-forearm were dissected away, leaving the IOL, wrist and elbow intact. Removal of non-ligamentous portions of the interosseous membrane was necessary to accurately determine insertions of the ligamentous central band. In some cases, small ligamentous fibers not associated with the ligamentous central band were neglected and excised. Removal of the mid-forearm soft tissue (especially muscles with partial insertions on the IOL) could have an effect on the measured IOL strains. For strains above 2%, when the IOL fibers are relatively taut, the effect of the lack of mid-forearm muscle was assumed negligible in this passive rotation model (with no active muscle forces).

A previously described method was used to generate 3-D curves to represent the IOL insertion sites on the radius and ulna¹⁶. Plexiglas registration blocks were attached near the IOL insertion sites on the radius and ulna. A CT scan was then obtained for each specimen. The

Plexiglas blocks were used to register the forearm geometry (including radial and ulnar IOL insertion sites) obtained from a CT scan with the data collected during the experiment¹⁸.

The radius, ulna, and IOL geometries were reconstructed from the CT data using in-house software and Nuages (freeware program, Bernard Geiger, France). Points on the ulnar and radial IOL insertion sites were also digitized from the geometric models, using Tecplot (Amtec Engineering, Inc, Bellevue WA). A continuous representation of the two insertion sites was obtained by fitting cubic splines to the digitized points. By connecting corresponding points on each insertion, this technique provides a representation of fibers of the IOL (**Figure 1**). Consistent with what is seen in the ligament, the fibers are modeled as running nearly parallel from one insertion to the other. The model assumes that ligament fibers originating at the proximal end of the radial insertion terminate at the proximal end of the ulnar insertion. Similarly, fibers originating at the middle of the radius insertion are assumed to terminate in the middle of the ulnar insertion, and so on.

To provide continuous kinematics of the radius relative to the ulna throughout a range of forearm rotation, an instrumented spatial linkage (ISL) was used. The ISL (EnduraTec Corporation, Minnetonka MN) has seven links connected by six rotary optical encoders that provide joint orientations. By combining data from all ISL encoders and with a knowledge of link lengths and orientations, the 3-D position and orientation of the free end can be determined with respect to the fixed end. The standard ISL was modified to increase rigidity of the joints and provide accuracies of approximately 0.2 mm and 0.2°.

The experimental configuration was established as follows. Two holes were drilled in the ulna, and it was bolted to a rigid fixture which held the forearm vertically. Next, the ISL was attached to the radius (from above) in a way that would allow full forearm rotation and would

not apply a significant force to the radius (**Figure 2**). An initial position of the radial registration block, ulnar registration block, and ISL endblocks were determined using a Microscribe 3DX digitizer (Immersion Corporation, San Jose CA) accurate to within 0.2 mm for position (manufacturer's stated accuracy). Sets of points from three orthogonal planes were collected for each block to establish local coordinate systems, using a previously described technique¹⁸. This procedure gave the initial relationship between the radius and the ulna and the fixed relationship between the ISL data and the IOL insertion site on the radius. The humerus was positioned such that the elbow was at 90° of flexion. The humerus was not rigidly fixed, thus the specimen was allowed to maintain neutral varus/valgus alignment. Each specimen was preconditioned by rotating the specimen through its range of motion ten times. Next, the forearm was manually rotated throughout its rotation, from supination to pronation and vice versa. That is, each forearm was rotated to the end of its passive range of motion, or its end-feel¹⁹. The ends of the passive range of motion were manually determined by a sudden rise in resistance forearm to rotation and noticeable rotation in the wrist. To help assure consistency, the same person manipulated all specimens. The encoder angles of the ISL were collected at 18Hz. During testing, the IOL and other soft tissues were kept moist with saline to minimize changes in the material properties of the soft tissue.

For calculation of strains relative to a stress-free reference state, the strain field in neutral rotation (with respect to the stress-free state) was determined by gluing small 1/16 inch diameter plastic markers to the IOL along local fiber directions. Markers were placed in the distal and proximal fiber regions near the radial and ulnar insertions. The forearm was placed in neutral rotation, so that the IOL lay in a single plane. A registration scale was placed in the field at the level of the dots. A digital image of the IOL was taken with the focal plane set to the plane of

the IOL surface. Another digital image was taken after the IOL was cut out of the forearm and placed on a thin film of saline (a near zero stress condition). The percent in-situ strain for the neutral reference position was subtracted from the neutral position fiber lengths to determine the reference stress-free fiber lengths.

The strain distributions across the fibers of the IOL were then determined throughout forearm rotation. The IOL fiber lengths were determined from the positions of the radial and ulnar IOL insertion sites throughout forearm rotation from the ISL data¹⁶. Strains were determined by accounting for the relative change in fiber length from stress-free reference length of IOL fibers (as calculated from the optical measurements described above).

The percent strains in distal, central, and proximal fibers of the IOL of each specimen were plotted. Percent strains in the IOL were plotted against normalized forearm rotation for each specimen (-1 representing full supination, zero representing neutral rotation and +1 representing full pronation). For statistical analysis, the IOL strain in distal, central, and proximal fibers in full pronation, neutral, and full supination rotations were compared. Two-factor ANOVA was performed followed by multiple contrast comparisons between IOL fiber location and forearm rotation position.

Results

Nine of the ten specimens exhibited similar trends in strain throughout forearm rotation. One specimen demonstrated decreasing (negative) strains in both pronation and supination, and strain data for this specimen was more than three standard deviations different from all other specimens at multiple comparison points. Thus, this specimen, that had no obvious pathology, was eliminated from the statistical analysis as a statistical outlier. Negative strains indicate the

degree of slackness in the ligament and do not indicate compressive strains or ligament shortening (Table 1, Figure 3). In reality, when negative strain is indicated, the distance between fiber insertions is less than the stress-free length, and the ligament fibers become slack and may fold, bunch together, etc. On average, the IOL became slack at 25% of full pronation, with more slackness in the distal fibers than the proximal fibers. In neutral rotation, the mean strain was approximately one percent throughout the fibers. Strain increased as the amount of supination increased. At full supination, strain varied across the fibers of the IOL, from approximately 6% strain in the distal fibers to 3% strain in the proximal fibers.

The forearm rotation range of motion, defined as relative motion between the radius and ulna only (not accounting for motions of the hand and wrist), varied between specimens. The mean rotation of the radius relative to the ulna at full pronation was 63 ± 13 degrees. The mean value of rotation at full supination was 52 ± 19 degrees.

Overall, the results show that the passive strain distribution is non-uniform and varies with forearm rotation. In general, the IOL is more slack in the distal fibers than the proximal fibers in pronation. In neutral rotation, IOL strain is relatively uniform, i.e. strain varies less than one percent across fibers. In supination, strain in the distal fibers is greater than strain in the proximal fibers. Nine of the ten specimens tested exhibited the largest strain in supination and were most slack in pronation. There was some variation in individual specimen behavior. For instance, three individual specimens showed slightly positive strains in the proximal fibers during pronation. However, the above description and Figure 3 summarize the overall trends in the results.

Discussion

The objective of this study was to measure the strain distribution in the interosseous ligament (IOL) of the forearm throughout a full range of passive rotation. The purpose of collecting this data was to determine the most appropriate technique for IOL reconstructive graft placement and tensioning. We have successfully collected the intended data. Our data demonstrates that passive IOL strain levels are dependent upon forearm rotation and that a variation of strain exists across IOL fibers in most forearm positions. The non-uniform patterns of strain are due to non-uniform changes in IOL fiber lengths as the radial and ulnar insertion sites move relative to each other in space.

As with any cadveric study, this study has several limitations. First of all, the specimens themselves represent a limitation. While the specimens come from a large range of ages that may appear generally representative, the results have implications primarily for forearm reconstruction due to severe injuries. These severe injuries are more likely in a younger population. The general population is capable of a mean amount of 80 degrees of pronation and 80 degrees of supination for the entire forearm, including rotations at the hand, wrist and elbow¹⁹. Thus, our measurements (full pronation at 63 ± 13 degrees and full supination at 52 ± 19 degrees) compare reasonably well with prior measurements of the general population. This basic measure indicates our specimen group was adequately representative.

Another limitation is the lack of active muscle forces and the removal of muscles (and other soft tissue in the mid-forearm). This study was intentionally performed passively and without external load for two reasons. First, when surgical grafts are placed, no external loads are present and the forearm must be rotated passively. Second, though rotation under load would provide important functional data, it is technically very difficult to properly implement. Because the forearm axis of rotation changes during forearm rotation, it is difficult to avoid extraneous

forces if the forearm is rotated under axial load. Also, the removal of muscle tissue in the mid-forearm could (even passively) affect the measured IOL strains. The presence of muscles could possibly cause the IOL fibers to take a nonlinear path between insertion sites. However, such effects are considered negligible at strains of 2% or greater, since the tension in the IOL fibers should cause the fibers to become straight in a passive model.

Strain in the IOL has been investigated previously in limited studies. Skahen et al. examined IOL strain in 6 preserved specimens¹⁻³. They found strain to be greatest in neutral rotation. This is not consistent with our findings, but the differences may be due to the fact that our specimens were fresh forearms (frozen), as opposed to preserved, since preservation is known to increase the stiffness of tissues. Also, the applied loads and the placement of the single sensor in that prior study may have affected the results. In a related study of 12 fresh specimens, Skahen et al. found the strain in the central band was greatest in pronation¹⁰. Again, the differences may be due to loading and the placement of the strain sensor. Also in both of the above prior studies, the strain is not measured from insertion to insertion, but only in the mid-substance. In an MRI study of the interosseous membrane, Nakamura et al. reported minimal changes in the ligamentous central third of the interosseous membrane, and concluded that the IOL must be taut throughout forearm rotation to provide stability²⁰. However, that study was done in alert human subjects, and muscle activity could provide loading that would account for differences in their conclusions. In addition, they did note that the membranous portions were wavy in pronation, which is consistent with our finding of slackness in the IOL in pronation. Finally, Manson et al reported average strains in the proximal and distal portions of the IOL at three distinct positions and during loading in a cadaveric model^{3,16}. While their reported proximal and distal strains in each position under load are not completely consistent with our

findings in unloaded passive rotation, the overall trend of higher strain in supination was also reported in that study. While none of these studies provides an excellent direct comparison or confirmation of our findings, the results of Nakamura et al. and Manson et al. provide substantial support for our findings of overall strain magnitudes with rotation.

There is more prior data on forearm rotation and load in the IOL. While overall strain should give an indication of load, external loading could change the relative position of the radius and ulna. Thus, the distance between insertion sites could change, which would alter the strain distribution. These studies applied an external load to the forearm, which could change the relative positions of the bones and thus alter the strain. Even so, it is instructive to examine these prior results in light of the current data. Some previous investigators that have studied the effect with the forearm under a compressive load and have found the greatest load to be transferred by the IOL in supination, consistent with this study^{12,13}. However, others have found that more load is transferred through the IOL in neutral rotation, which contradicts the other studies and the current results^{14,21}. All of these studies have reported the lowest load transfer in pronation, which is also consistent with this study. Our experimental configuration did not constrain varus-valgus alignment, such that there are no forces to cause alignment other than neutral. Markolf et al. has shown, however, that varus-valgus positioning of the forearm greatly affects tautness of the IOL¹²⁻¹⁵. All cadaveric studies are limited in the ability to simulate in-vivo radioulnar positions, especially without muscle forces. Thus, inconsistencies in varus-valgus positioning may explain some of the discrepancies between studies.

The results of this study indicate that strain in the IOL is highly dependent upon forearm rotation. Because it closely represents the clinical situation during reconstruction and early rehabilitation, we believe the current data is very relevant as a basis for developing an IOL

reconstruction. Our data suggest that any IOL replacement graft should be tensioned in supination, so that forearm supination is not limited. If an IOL replacement graft were tensioned in pronation or neutral, high strains may occur when the forearm begins to rotate toward supination. Graft tension may rise sharply enough that forearm supination could be limited.. This data also suggests that reconstructive grafts for the IOL should be located distally for load transfer in supination and should be located proximally for load transfer in pronation. Thus, the data suggests that to simulate the normal function of the IOL, a double bundle reconstruction may be required. Also, because one specimen demonstrated a different strain pattern, the surgeon should always keep anatomic variation in mind and should verify that passive forearm rotation is not constrained by any selected graft positioning and tensioning. While this study did not address graft angle, we believe grafts should be placed anatomically to match distal and proximal ligamentous bundles. A prior study by Skahen et al. indicates that the IOL is oriented obliquely at approximately 21° from the forearm axis ³.

Thus, we believe the basic parameters for a functional IOL reconstruction have now been identified. Certainly more experimental work to evaluate such reconstructions is needed before such reconstructions can be clinically recommended. The current data, in combination with prior reports, provides a foundation for further development.

ACKNOWLEDGEMENTS

This work was supported by The Whitaker Foundation. The authors also thank Thomas Vikoran for his technical assistance.

REFERENCES

1. Hotchkiss, R. N.; An, K. N.; Sowa, D. T.; Basta, S.; and Weiland, A. J.: An anatomic and mechanical study of the interosseous membrane of the forearm: pathomechanics of proximal migration of the radius. *J Hand Surg* 1989; 14A: 256-61.
2. Pfaeffle, H. J.; Tomaino, M. M.; Grewal, R.; Xu, J.; Boardman, N. D.; Woo, S. L.-Y.; and Herndon, J. H.: Tensile properties of the interosseous membrane of the human forearm. *Journal of Orthopaedic Research* 1996; 14: 842-5.
3. Skahen, J. R., 3rd; Palmer, A. K.; Werner, F. W.; and Fortino, M. D.: The interosseous membrane of the forearm: anatomy and function. *Journal of Hand Surgery* 1997; 22A: 981-5.
4. Essex-Lopresti, P.: Fractures of the radial head with distal radio-ulnar dislocation. *The Journal of Bone and Joint Surgery* 1951; 33B: 244-247.
5. Hotchkiss, R. N.: Injuries to the interosseous ligament of the forearm. *Hand Clinics* 1994; 10: 391-8.
6. Graham, T. J.; Fischer, T. J.; Hotchkiss, R. N.; and Kleinman, W. B.: Disorders of the forearm axis. *Hand Clinics* 1998; 14: 305-16.
7. Trousdale, R. T.; Amadio, P. C.; Cooney, W. P.; and Morrey, B. F.: Radio-ulnar dissociation. A review of twenty cases. *Journal of Bone & Joint Surgery* 1992; 74A: 1486-97.
8. Edwards, G. S., Jr., and Jupiter, J. B.: Radial head fractures with acute distal radioulnar dislocation. Essex-Lopresti revisited. *Clinical Orthopaedics & Related Research* 1988; 234: 61-9.
9. Morrey, B. F.; Askew, L.; and Chao, E. Y.: Silastic prosthetic replacement for the radial head. *Journal of Bone & Joint Surgery* 1981; 63A: 454-8.
10. Skahen, J. R., 3rd; Palmer, A. K.; Werner, F. W.; and Fortino, M. D.: Reconstruction of the interosseous membrane of the forearm in cadavers. *Journal of Hand Surgery* 1997; 22A: 986-94.
11. Palmer, A. K., and Werner, F. W.: The triangular fibrocartilage complex of the wrist--anatomy and function. *Journal of Hand Surgery* 1981; 6A: 153-62.
12. Birkbeck, D. P.; Failla, J. M.; Hoshaw, S. J.; Fyhrie, D. P.; and Schaffler, M. The interosseous membrane affects load distribution in the forearm. *J Hand Surg* 1997; 22A: 975-80.
13. Markolf, K. L.; Lamey, D.; Yang, S.; Meals, R.; and Hotchkiss, R.: Radioulnar load-sharing in the forearm. A study in cadavera. *Journal of Bone & Joint Surgery* 1998; 80A: 879-88.
14. Pfaeffle, H. J.; Fischer, K. J.; Manson, T. T.; Tomaino, M. M.; Herndon, J. H.; and Woo, S. L.-Y.: A new methodology to measure load transfer through the forearm using multiple universal force sensors. *Journal of Biomechanics* 1999; 32: 1331-5.

15. Schneiderman, G.; Meldrum, R. D.; Bloebaum, R. D.; Tarr, R.; and Sarmiento, A.: The interosseous membrane of the forearm: structure and its role in Galeazzi fractures. *Journal of Trauma-Injury Infection & Critical Care* 1993; 35: 879-85.
16. Manson, T. T.; Pfaeffle, H. J.; Herndon, J. H.; Tomaino, M. M.; and Fischer, K. J.: Forearm rotation alters interosseous ligament strain distribution. *J Hand Surg* 2000; 25A: 1058-63.
17. Woo, S. L.-Y.; Orlando, C. A.; Camp, J. F.; and Akeson, W. H.: Effects of postmortem storage by freezing on ligament tensile behavior. *J Biomech* 1986; 19: 399-404.
18. Fischer, K. J.; Manson, T. T.; Pfaeffle, H. J.; Tomaino, M. M.; and Woo, S. L.-Y.: A method for measuring joint kinematics designed for accurate registration of kinematic data to models constructed from CT data. *J Biomech* 2001; 34: 377-83.
19. Norkin, C. C., and White, D. J.: *Measurement of Joint Motion: A Guide to Goniometry*. Philadelphia: F. A. Davis, 1995: 241.
20. Nakamura, T.; Yabe, Y.; Horiuchi, Y.; and Yamazaki, N.: Three-dimensional magnetic resonance imaging of the interosseous membrane of forearm: a new method using fuzzy reasoning. *Magn Reson Imaging* 1999; 17: 463-70.
21. Pfaeffle, H. J.; Fischer, K. J.; Manson, T. T.; Tomaino, M. M.; Woo, S. L.; and Herndon, J. H.: Role of the forearm interosseous ligament: is it more than just longitudinal load transfer? *J Hand Surg* 2000; 25A: 683-8.

TABLES AND FIGURES

Table 1 Average strain in the IOL in the distal, central and proximal fibers at forearm pronation, neutral rotation and supination.^{a,b} (n = 9)

Figure 1: Computer reconstruction of radius, ulna and IOL showing representative ligament fibers between points on the IOL insertion of radius and points on the IOL insertion of the ulna. Though the IOL is a continuous tissue with a continuous distribution of fibers, these lines demonstrate fiber directions.

Figure 2 Experimental configuration showing the measurement equipment and the forearm mounted on the test fixture.

Figure 3 Plot of mean strain vs. normalized forearm rotation for proximal, central, and distal fibers. Forearm rotation is full supination at -1, neutral rotation at zero and full pronation at +1.

Table 1 Average strain in the IOL in the distal, central and proximal fibers at forearm pronation, neutral rotation and supination.^{a,b} (n = 9)

mean (s.d.) (%)	Distal Fiber	Central Fiber	Proximal Fiber
Pronation	-4.4 (5.7) [†]	-3.5 (4.2)	-2.6 (3.6) [†]
Neutral	0.5 (2.3)	0.6 (1.7)	0.8 (1.4)
Supination	6.0 (1.4) [‡]	4.5 (1.4)	3.1 (1.9) [‡]

^a Note negative values indicate the amount of slackness in the IOL, not compressive strains.

^b Forearm rotation position changes always resulted in significant differences ($p < 0.05$) in strain for all fiber groups.

[†] Significantly different strains in pronation ($p < 0.05$).

[‡] Significantly different strains in supination ($p < 0.05$).




Figure 1: Computer reconstruction of radius, ulna and IOL showing points on the IOL insertion of radius connected to points IOL insertion of the ulna to represent IOL fibers.

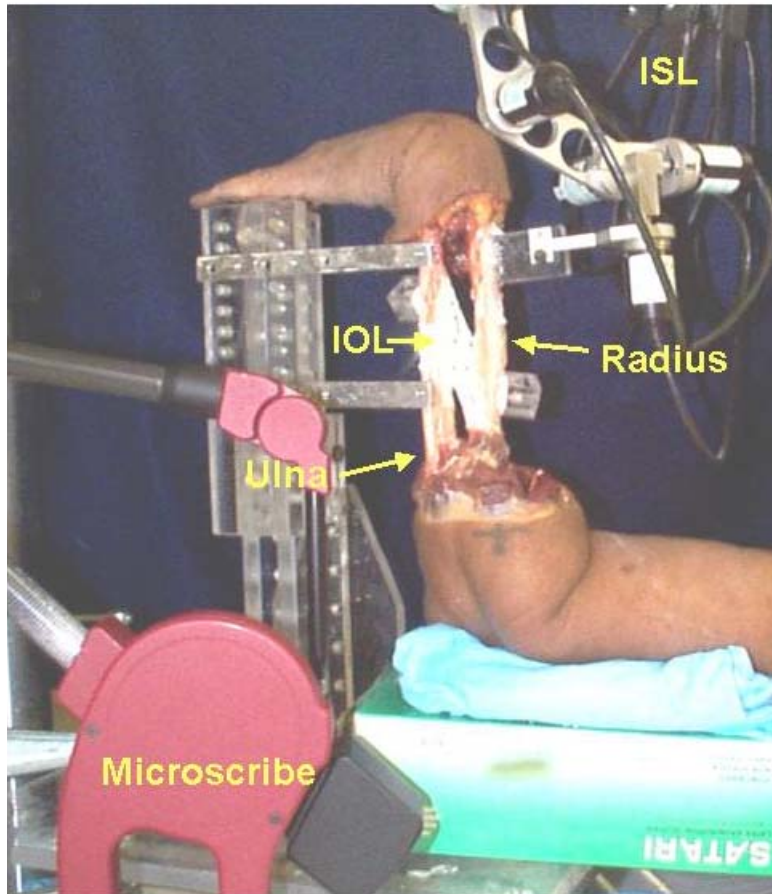


Figure 2 Experimental configuration showing the measurement equipment and the forearm mounted on the test fixture.

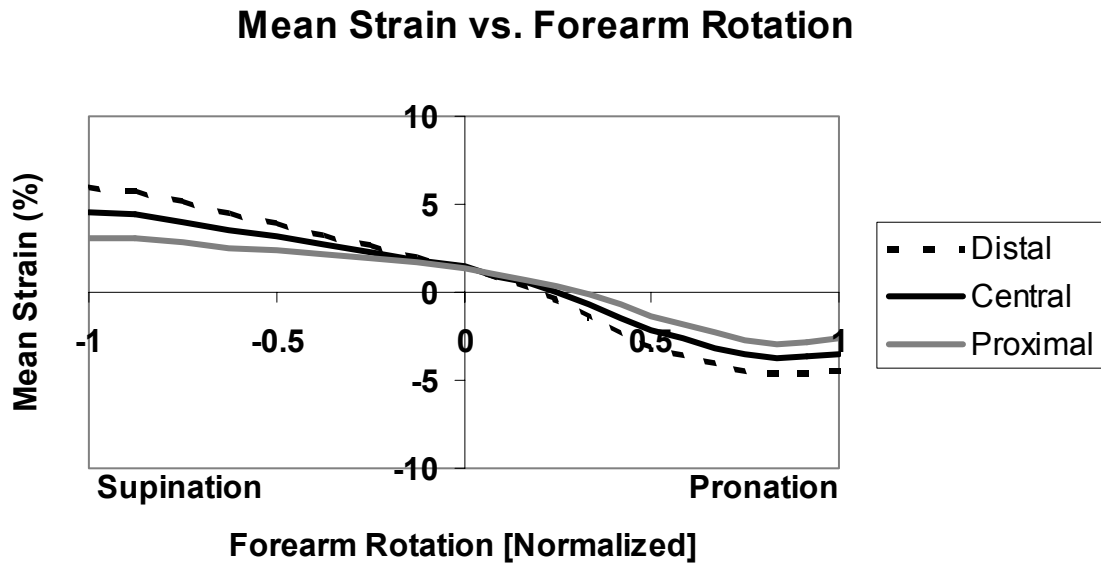


Figure 3 Plot of mean strain vs. normalized forearm rotation for proximal, central, and distal fibers.. Forearm rotation is full supination at -1 , neutral rotation at zero and full pronation at $+1$.